

## Epidemiology of HTLV-Associated Leukemia

W. A. Blattner, D. W. Blayney, E. S. Jaffe, M. Robert-Guroff, V. S. Kalyanaraman, and R. C. Gallo

### A. Introduction

Type-C retroviruses have long been implicated in the etiology of leukemia and lymphoma in various animal species. Animal models exist for exogenous, horizontal, transmission of these naturally occurring RNA tumor viruses in animals and are especially well characterized for cat, cow, and some other species [21]. Human T-cell leukemia-lymphoma virus (HTLV) is the first type-C retrovirus consistently isolated and associated with specific human malignancies. It is distinct from previously identified animal retroviruses by molecular [15] and immunologic studies [10, 16, 17]. It is an exogenous virus that must be acquired by infection (i.e., not transmitted in the germ line), since HTLV proviral sequences are present in DNA of neoplastic T cells, but not in DNA of nonneoplastic B cells from the same patient [7] or in normal tissues [15].

In this report we summarize clinical and epidemiologic features which suggest that HTLV is etiologically linked to certain malignancies. Our data demonstrate that HTLV is associated with cases of mature T-cell leukemia-lymphoma with common clinical features. These cases tend to cluster in a restricted distribution where HTLV infection is prevalent. Occasional patients from virus nonendemic areas probably acquired HTLV infection prior to developing their T-cell leukemia-lymphoma through travel into HTLV endemic areas and close contact with residents in these areas.

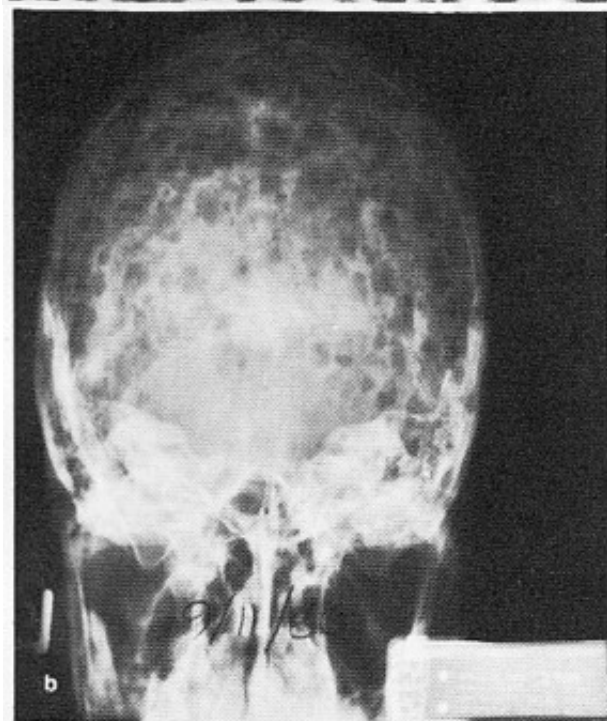
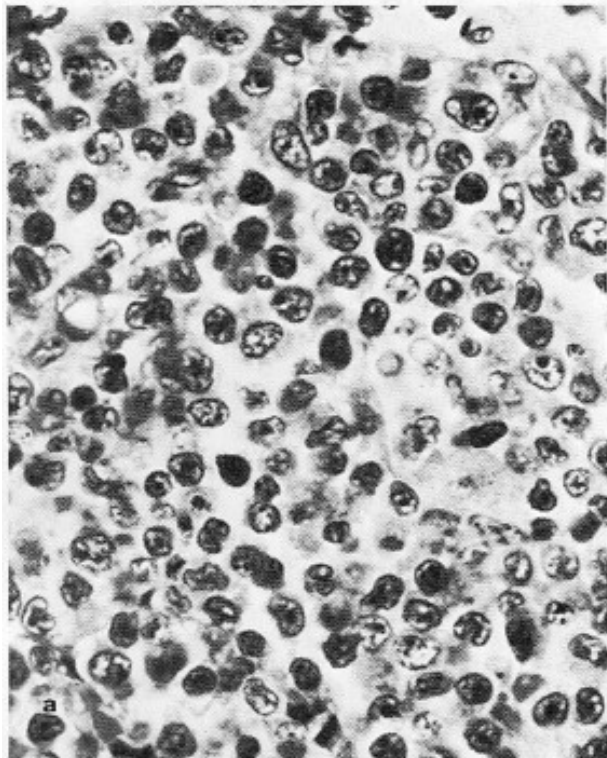
### B. Materials and Methods

Samples from various patient and normal populations were submitted as frozen or lyophilized serum or plasma. The clinical and pathologic diagnoses were as recorded by the submitting investigator except for certain cases where pathologic material was reviewed by one of us (E.J.). Serum antibodies to a disrupted whole virus preparation were detected by a modification to the technique previously reported [14]. Natural antibody to the major core protein p24 of HTLV was detected by a radio-immune precipitation (RIP) as previously described [9].

### C. Clinical and Pathologic Features

The majority of cases from which HTLV has been isolated, or in which HTLV antibodies have been detected, share many common features. Summarized in Table 1 are the clinical and pathologic characteristics of HTLV-positive cases from the Western Hemisphere and elsewhere (details of HTLV-positive cases from Japan are not included in this report). In all cases in the series, and in cases from Japan [11, 18], HTLV has an association with lymphoma or leukemia of mature differentiated T cells. In current immunopathologic nomenclature, the broad category of malignancies of mature T cells includes T-cell chronic lymphocytic leukemia, cutaneous T-cell lymphomas (CTCL) (mycosis fungoides/Sezary syndrome), peripheral T-cell lymphoma, lymphosarcoma cell leukemia (T-LCL), and adult T-cell leukemia-lym-

phoma (ATL). As shown in Table 1, HTLV is most commonly associated with peripheral T-cell lymphomas (classification in the working formulation [1] as large cell, diffuse mixed, or immunoblastic cell type), TLCL, and ATL. Although two of these



**Fig. 1. a** Posterior auricular lymph node from case 16. An admixture of small and large atypical lymphoid cells is present. Hematoxylin and eosin,  $\times 430$ . **b** Plain skull radiograph for case 16. Multiple small lytic lesions are present throughout the calvarium

cases were classified as CTCL, this association is rare since they are the only two out of over 200 cases from the United States, England, and western Europe that were positive for HTLV serum antibodies.

As is evident from Table 1, the histopathologic diagnoses given vary considerably. There are, however, certain morphologic features shared by most of these tumors. The tissues show diffuse proliferation of a pleomorphic population of lymphoid cells (Fig. 1a). The cells tend to vary considerably both in size and shape. In most cases, cells from all points in the spectrum are present in equal proportions, and such cases are designated as diffuse, mixed cell type by both the Rappaport classification and the working formulation [1]. In other cases, one large lymphoid cell type predominates, and such cases are designated as diffuse large cell, or diffuse large cell, immunoblastic lymphoma, based on the characteristics of the proliferating cells. An inflammatory background is normally not evident.

The histopathologic features described above are similar to those seen with certain other peripheral T-cell lymphomas not associated with HTLV. Thus, there are no specific pathologic features that can be recognized at this point as indicating an HTLV-associated leukemia/lymphoma.

Similarly, there is quite a spectrum in the clinical presentation of cases, which may present as lymphoma, leukemia, or lymphoma with leukemic involvement. Some cases appear associated with fulminant and rapidly progressive disease, whereas others have a much more indolent and chronic clinical course. Thus, the exact relationship of HTLV to a specific clinical entity is far from established. Therefore, systematic surveys in HTLV-endemic and nonendemic areas, with special attention to precise immunologic classification of malignant cells, will be needed to clarify these relationships further. In addition the recent observation of antibody-negative, antigen-positive cases of CTCL (C. Saxinger, personal communication) point to a need for caution in defining virus-disease relationships. Ultimately "molecular" epidemiologic studies of defined disease categories will need to be undertaken before final conclusions can be drawn.

**Table 1.** Features of HTLV-associated T-cell malignancies

Case No.	Patient	Age/sex	Race <sup>a</sup>	Place of birth	Diagnosis	Clinical signs <sup>b</sup>	Hypercalcemia	WBC × 10 <sup>9</sup> 3/liter	Evidence for HTLV	
									Virus isolation	Antibody to HTLV
1	C.R.	28/M	B	Alabama	Pleomorphic CTCL <sup>c</sup>	L, D, O	+	7.1	+	+
2	M.J.	50/M	W	Massachusetts	Sezary syndrome <sup>c</sup>	L, D	-	5.2	+	+
3	M.O.	32/M	W	Washington State	T-hairy cell leukemia <sup>c</sup>	S, H	+	2.9	+	+
4	P.L.	29/F	B	Florida	T-malignant lymphoma, diffuse mixed cell type <sup>c</sup>	L, S, H	+	9.3	N.P.	+
5	E.T.	38/M	B	Virginia	T-lymphoblastic leukemia	L, H	+	235	N.P.	+
6	W.A.	24/M	B	Georgia	T-malignant lymphoma, diffuse mixed cell type <sup>c</sup>	L, D	-	5.8	+	+
7	J.N.	76/M	Aleut	Alaska	Malignant lymphoma diffuse large cell type <sup>c</sup>	S, D	-	4.2	N.P.	+
8	M.B.	64/F	B	St. Lucia	T-malignant lymphoma, diffuse mixed cell type <sup>c</sup>	L, S, H, D	-	435	+	N.P.
9	M.I.	32/F	B	Granada	T-malignant lymphoma diffuse mixed cell type <sup>c</sup>	L, S, H, D, O	-	40	+	+
10	C.M.	31/F	B	St. Vincent	T-lymphosarcoma cell leukemia (ATL)	L	+	39	N.P.	+
11	J.T.	21/F	B	Trinidad	T-malignant lymphoma, diffuse large cell type (ATL)	L, S, H, D, A	+	31	N.P.	+
12	M.H.	49/F	B	Jamaica	T-malignant lymphoma diffuse large cell type (ATL)	L, S	+	17	N.P.	+
13	E.L.	41/F	B	Barbados	T-chronic lymphocytic leukemia (ATL)	L, O	-	40	N.P.	+
14	M.W.	54/F	B	West Indies	T-immunoblastic leukemia (ATL)		+	57	N.P.	+

15	S.W.	45/F	B	Guyana	T-malignant lymphoma immunoblastic type (ATL)	L	+	67	N.P.	+
16	J.S.	33/M	W	Ecuador	T-malignant lymphoma diffuse mixed cell type <sup>c</sup>	L, H, O	+	20	N.P.	+
17	U.K.	45/M	W	Israel	T-malignant lymphoma diffuse large cell type <sup>c</sup>	L, S, H, D, O	+	18	+	+

<sup>a</sup> W, Caucasian; B, black; Aleut, Aleutian Indian

<sup>b</sup> L, lymphnode involvement; S, splenomegaly; H, hepatomegaly; D, skin involvement; A, ascities; O, osteolytic bone lesions

<sup>c</sup> Pathology material reviewed by E.J. (ATL) cases reviewed by Daniel Catovsky, Hammersmith Hospital, London, and although called other diagnoses as noted, represent cases with features of adult T-cell leukemia – lymphoma

One of the striking features of these cases [4], as well as ATL cases from Japan [20], is the frequent occurrence of idiopathic hypercalcemia. In some cases (Fig. 1 b) radiographs show multiple lytic bone lesions mimicking multiple myeloma or metastatic solid tumors. In these cases, no lymphoma cells are seen in association with these lesions but rather osteoclast activity and reactive granulation tissue. This pathologic feature may be a reflection of HTLV-activated lymphokine production, although for cases 4, 16, and 17, the lymphokine, osteoclast activating factor (OAF) was not detectable in bioassay [3]. A variety of lymphokines are produced by HTLV-infected cell lines in vitro, suggesting that integration of proviral DNA results in depression of host genes including those for various lymphokines [8]. Viral-associated cases with hypercalcemia provide a convenient setting to test this model.

#### D. Disease Associations and Case Clusters

To evaluate the relationship of HTLV infection and disease, sera from over 900 cases of adult and childhood malignancies from diverse geographic areas have been tested for HTLV antibodies [6]. As shown in Table 2, only 55 of 914 were positive. None of the nonlymphoreticular neoplasms were positive, indicating that HTLV is probably trophic for cells of the lymphoreticular compartment. The bulk of the

positives were from patients with definite T-cell malignancies. The remaining nine were from patients with lymphoid and/or myeloid leukemias from Japan. Since some of these cases come from the viral endemic area and/or in some cases have been extensively transfused, the etiologic significance of this association remains to be established.

HTLV is most closely associated with ATL diagnosed in Japan, and 29 of the 34 patients in this series were positive [6]. Among cases of T-Cell non-Hodgkin's lymphoma (T-NHL), 6 of 12 from Japan were also positive. These positive T-NHL cases appear to share features with cases from the United States and elsewhere as recorded in Table 1. The eight cases of HTLV-positive ATL from the Caribbean region (cases 8–15 in Table 1 in this series) confirm the propensity for geographic clusters of HTLV-associated cases to share clinical and pathologic features [2, 4].

Studies of normal populations provide a model for examining the role of HTLV as an etiologic agent. The detection of HTLV antibodies in relatives of cases is of interest since it may reflect the infectivity of HTLV. In Table 3 we summarize the data on members in nine families of HTLV-positive malignancies. Except for one family from Japan in which four of eight members were antibody positive, in all other cases only one first-degree relative was found to be positive. The fact that both spouses and blood relatives were positive leads us to suspect horizontal rather than vertical

**Table 2.** HTLV-specific antibodies in lymphoid and nonlymphoid malignancy

Disease	Number positive/number tested by country of origin			
	United States or Europe	West Indies	Japan	Total
T-lymphocytic	9/338 <sup>a</sup>	8/9	29/34	46/381
Unclassified and B-lymphocytic	0/258	0/3	4/43	4/304
Myeloid	0/108	0/2	5/27	5/137
Nonlymphoreticular	0/86	N.T.	N.T.	0/86

<sup>a</sup> Cases 16 and 17 in Table 1, although born in Ecuador and Israel respectively, are included here since they were detected as part of a survey of T-cell cases at the National Institute of Health, Bethesda, Maryland, United States

Individuals tested	Number positive/number tested by country of origin		
	United States or Europe	West Indies	Japan
Relatives of HTLV cases	1/8	3/16	13/31
Random donors	4/1120 <sup>a</sup>	12/337	39/404 <sup>b</sup> 9/509 <sup>c</sup>

**Table 3.** HTLV-specific antibodies in normals

<sup>a</sup> Three of the positives were in blacks from a sample of 130 normals from Georgia. The remaining positive was from a black woman from a sample of 158 normal blood bank donors in Washington, DC

<sup>b</sup> ATL-nonendemic area of Japan

<sup>c</sup> ATL-endemic area of Japan

transmission. Since relatives of these cases shared a common environment, prospective follow-up of exposed relatives of newly diagnosed HTLV-positive cases should help clarify the mode of HTLV transmission [19].

Limited surveys of donors from populations in the United States, western Europe, Japan, and the Caribbean (Table 3) demonstrate that HTLV infection in the general population is limited. Among study subjects from the United States and Europe only three had HTLV antibodies. The three positives were from a sample of specimens submitted to the Georgia State Health Department serology reference laboratory. Many of the United States-born cases of HTLV leukemia-lymphoma, as well as the normal people with HTLV antibodies, are blacks from the southeast United States. This geographic and racial clustering suggests that HTLV infection may have a restricted distribution and/or racial predilection. Further analysis of other populations in this region as well as surveys in other areas of the United States should clarify this relationship [3]. In Japan, sera from ATL nonendemic regions were HTLV antibody negative, while a low prevalence of virus antibody positives was seen in the ATL endemic region of Kyushu (Robert-Guroff et al., unpublished observations). Similarly a population-based survey of normals in the Caribbean revealed a low prevalence of HTLV-positive serology [2].

### E. HTLV Infection and Adult T-cell Malignancy

The frustrating failures of virologists in the past to demonstrate and isolate a uniquely human type-C RNA tumor virus etiologically linked with leukemia or lymphoma has led to the belief that retroviruses play no role in these or other human malignancies. Human T-cell leukemia-lymphoma virus (HTLV) is the first human virus of this class consistently identified in association with a specific type of human leukemia-lymphoma [5, 12, 13]. The epidemiologic data summarized here demonstrate that HTLV is associated with several malignancies of the T cell, but not solid tumors or other hematopoietic tumors [6]. Although the role of HTLV as an etiologic agent is not established, it is striking that the distribution of cases is limited to a relatively narrow spectrum of mature T-cell leukemia-lymphoma cases with common features.

In further support of the notion that HTLV and T-cell leukemia-lymphoma are related is the limited distribution of HTLV infection in the general population. Although most dramatic in Japan, where HTLV seropositivity appears geographically associated with clusters of ATL [11, 18], a similar pattern is emerging in the Caribbean [2, 4] and more recently in the southeastern United States blacks [3]. In two cases from the United States (case 2,

MJ, case 3, M.O.) both the clinical and epidemiologic features were distinct from the bulk of other cases. Both patients, however, had histories of travel to and close contact with persons in viral endemic areas. These exceptions to the rule provide further evidence for a virus-disease relationship since it is likely that their HTLV infection was acquired in viral endemic regions. Studies of migrants into HTLV endemic regions may prove especially informative in further delineating etiologic relationships.

In summary, we postulate that HTLV, unlike other putative tumor viruses, is not widespread in distribution but rather is limited to certain regions of the world and within limited areas of some countries (e.g., southwestern Japan). In at least three areas, Japan, the Caribbean, and the southeastern United States, HTLV-associated disease is a mature adult T-cell leukemia-lymphoma. Identification of cases in some other areas of the world suggests that a similar pattern of virus prevalence and disease occurrence will emerge. Thus, although further studies will be needed to establish a causal relationship, the story thus far is similar to that of the retrovirus association with leukemia-lymphoma in animals in which satisfaction of Koch's postulates has established an etiologic role for C-type retroviruses.

## References

- Berard CW, Greene MH, Jaffe ES, Magrath I, Ziegler J (1981) A multidisciplinary approach to non-Hodgkins lymphomas. *Ann Int Med* 94:218-235
- Blattner WA, Kalyanaraman VS, Robert-Guroff M, Lister TA, Galton DAG, Sarin P, Crawford MH, Catovsky D, Greaves M, Gallo RC (1982) The human type C retrovirus, HTLV, in blacks from the Caribbean, and relationship to adult T-cell leukemia/lymphoma. *Int J Cancer* (in press)
- Blayney DW, Jaffe ES, Fisher RI, Schechter GP, Cossman J, Robert-Guroff M, Kalyanaraman VS, Blattner WA, Gallo RC (to be published) The human T-cell leukemia/lymphoma virus (HTLV), lymphoma, lytic bone lesions, and hypercalcemia. *Ann Int Med*
- Catovsky D, Greaves MF, Rose M, Galton DAG, Goolden AWG, McCluskey DR, White JM, Lampert I, Bourikas G, Ireland R, Bridges JM, Blattner WA, Gallo RC (1982) Adult T-cell lymphoma-leukemia in blacks from the West Indies. *Lancet* 1:639-643
- Gallo RC, Poiesz BJ, Ruscetti FW (1981) Regulation of human T-cell proliferation: T-cell growth factor and isolation of a new class of type-C retroviruses from human T-cells. In: Neth R, Gallo RC, Graf T, Mannweiler K, Winkler K (eds) *Modern Trends in Human Leukemia*, vol. IV. Springer, Berlin Heidelberg New York
- Gallo RC, Kalyanaraman VS, Sarngadharan MG, Sliiski A, Vonderheid EC, Maeda M, Nakao Y, Yamada K, Ito Y, Gutensohn N, Murphy S, Bunn PA, Catovsky D, Greaves MF, Blayney DW, Blattner WA, Jarrett WFH, zur Hausen H, Seligmann M, Brouet JC, Haynes BF, Jegasothy BV, Jaffe E, Cossman J, Broder S, Fisher RI, Golde DW, Robert-Guroff M (to be published) *N Engl J Med*
- Gallo RC, Mann D, Broder S, Ruscetti FW, Maeda M, Kalyanaraman VS, Robert-Guroff M, Reitz MS, Jr (to be published) Human T-cell leukemia/lymphoma virus (HTLV) is in T- but not B-lymphocytes from a patient with cutaneous T-cell lymphoma. *Proc Natl Acad Sci USA*
- Gootenberg JF, Ruscetti FW, Mier JW, Gazdar A, Gallo RC (1981) Human cutaneous T-cell lymphoma and leukemia cell lines produce and respond to T-cell growth factor. *J Exp Med* 154:1403-1418
- Kalyanaraman VS, Sarngadharan MG, Bunn PA, Minna JD, Gallo RC (1981) Antibodies in human sera reactive against an internal structural protein (p24) of human T-cell lymphoma virus. *Nature* 294:271-273
- Kalyanaraman VS, Sarngadharan MG, Poiesz BJ, Ruscetti FW, Gallo RC (1981) Immunological properties of a type-C retrovirus isolated from cultured human T-lymphoma cells and comparison to other mammalian retroviruses. *J Virol* 38:906-915
- Kalyanaraman VS, Sarngadharan MG, Nakao Y, Ito Y, Gallo RC (1982) Natural antibodies to the structural core protein (p24) of the human T-cell leukemia (lymphoma) retrovirus (HTLV) found in sera of leukemia patients in Japan. *Proc Natl Acad Sci USA* 79:1653-1657
- Poiesz BJ, Ruscetti FW, Gazdar AF, Bunn PA, Minna JD, Gallo RC (1980) Detection and isolation of type-C retrovirus particles from fresh and cultured lymphocytes of a patient with cutaneous T-cell lymphoma. *Proc Natl Acad Sci USA* 77:745-749
- Poiesz BJ, Ruscetti FW, Reitz MS, Kalyanaraman VS, Gallo RC (1981) Isolation of a

- new type-C retrovirus (HTLV) in primary cultured cells of a patient with Sezary T-cell leukemia. *Nature* 294:268-271
14. Posner LE, Robert-Guroff M, Kalyanaraman VS, Poiesz BJ, Ruscetti FW, Fossieck B, Bunn PA, Minna JD, Gallo RC (1981) Natural antibodies to the retrovirus HTLV in patients with cutaneous T-cell lymphomas. *J Exp Med* 154:333-346
  15. Reitz MS, Poiesz BJ, Ruscetti FW, Gallo RC (1981) Characterization and distribution of nucleic acid sequences of a novel type-C retrovirus isolated from neoplastic human T-lymphocytes. *Proc Natl Acad Sci USA* 78:1887-1891
  16. Rho HM, Poiesz BJ, Ruscetti FW, Gallo RC (1981) Characterization of the reverse transcriptase from a new retrovirus (HTLV) produced by a human cutaneous T-cell lymphoma cell line. *Virology* 112:355-360
  17. Robert-Guroff M, Ruscetti FW, Posner LE, Poiesz BJ, Gallo RC (1981) Detection of the human T-cell lymphoma virus p19 in cells of some patients with cutaneous T-cell lymphoma and leukemia using a monoclonal antibody. *J Exp Med* 154:1957-1964
  18. Robert-Guroff M, Nakao Y, Notake K, Ito Y, Aliaki A, Gallo RC (1982) Natural antibodies to the human retrovirus, HTLV, in a cluster of Japanese patients with adult T-cell leukemia. *Science* 215:975-978
  19. Robert-Guroff M, Kalyanaraman VS, Blattner WA, Popovic M, Sarngadharan MG, Maeda M, Blayney DW, Catovsky D, Bunn PA, Shibata A, Nakao Y, Ito Y, Aoki T, Gallo RC (to be published) Evidence for HTLV-infection of family members of HTLV-positive T-cell leukemia/lymphoma patients. *J Exp Med*
  20. Uchiyama T, Yodoi J, Sagawa K, Takatsuki K, Uchino H (1977) Adult T-cell leukemia: clinical and hematologic features of 16 cases. *Blood* 50:481-492
  21. Wong-Staal F, Gallo RC (to be published) Retroviruses and leukemia. In: Gunz F, Henderson E, (eds) *Leukemia*. Grune and Stratton, New York