

CHAPTER IV

Pathology of the Radiation Chimaera

INTRODUCTION

The pathology of the radiation chimaera has been studied systematically in the mouse^{99, 122, 184, 449}, the rat^{14, 18}, the rabbit³²⁵ and the rhesus monkey⁴⁴⁶. Some information has been published on other species including the dog^{166, 330, 400} and man²⁶³, but these observations are of an incidental nature. Moreover, the interpretation of the findings in the latter cases has usually been complicated by the fact that the identification of cells of the donor type has either not been performed or has yielded equivocal results so that it is not possible to be sure that the lesions encountered were characteristic of the chimaeric state.

The most important complication of an established graft of foreign bone marrow is secondary disease and since this condition is an entirely new pathological entity, emphasis is placed in this chapter on the pathological changes which have been found to accompany this disease. In order to identify the characteristic pathology of secondary disease it is obvious that the lesions have to be clearly differentiated from those due to whole body irradiation. This is the reason that the bone marrow syndrome will be described first in a separate section.

In several studies the conditions of the bone marrow transplantation were such that a delayed rejection of the graft took place in a proportion of the animals, while others remained stable chimaeras which developed secondary disease at about the same time. Because investigators were unaware of these two possibilities, particularly in early studies on the subject, some confusion arose concerning the nature of the lesions which were observed in such mixed groups of animals. The pathology which is considered typical for a delayed rejection of the bone marrow graft has therefore been treated more extensively in a later section.

The bone marrow syndrome

In the mouse, irradiation with lethal doses below 1200 r invariably leads to death from the bone marrow syndrome if no treatment is given. Since the pathology of the bone marrow syndrome is well known, those aspects necessary to differentiate this condition from secondary disease will be more fully discussed.

In most animal species bone marrow aplasia following lethal irradiation develops in about 2–3 days (Plate IV: 1). After 24 hours, mature granulocytes and megakaryocytes are the only haemopoietic cells left. After 48 hours an acellular marrow is found, which consists of reticular cells dispersed between dilated sinusoids. A few megakaryocytes may still be found. In men and monkeys infiltration with plasma cells and histiocytes—cells which are relatively radioresistant—is conspicuous. The state of aplasia persists till the death of the animal. Small groups of stem cells which consist mainly of erythroblasts may be noted during this interval and probably represent abortive attempts at regeneration.

Atrophy similarly develops in the lymphatic tissues of the lymph nodes (Plate IV: 2), spleen (Plate IV: 3), intestinal tract and thymus. After 24 hours depletion of lymphoid cells is pronounced and the lymphatic follicles have disappeared. However, even after *supra*lethal doses small numbers of mature lymphoid cells may be found dispersed in the reticular stroma and a further decrease in cellularity occurs in the following days. In a proportion of the animals large reticular cells and histiocytes with swollen nuclei and prominent nucleoli, sometimes displaying abnormal mitoses, are found in the follicular remnants. Frequently, the surrounding tissue and the medullary cords are heavily infiltrated with plasma cells.⁹⁵ It has been stated that this reticulo-histiocytic and plasmocellular reaction is a response to antigens from invading micro-organisms but this hypothesis seems to have been made less likely by the recent discovery of a similar cellular reaction in irradiated germfree animals³⁶. Others have investigated this phenomenon and have ascribed it to an immunological reaction against the breakdown products of damaged and dead cells which are released in the first few days after irradiation.

The lymphatic sinusoids are dilated and filled at first with histiocytic cells, and after the first week with erythrocytes which are sometimes partly engulfed by macrophages. The latter finding is a reflection of the concurrent haemorrhagic diathesis. In a

minority of animals small groups of lymphoblasts may be found at the end of the first week, which probably represent abortive regeneration.

The aplasia of the blood-forming organs is reflected in the peripheral blood by pancytopenia. The rate of disappearance of the various mature cellular elements is mainly due to a complete inhibition of their production by the radiosensitive stem cells in the haemopoietic tissues and determined, therefore, by the normal life span of the mature radioresistant elements in the blood. An exception are lymphocytes which die in interphase soon after irradiation both in the lymphatic tissues as well as in the peripheral blood. In the case of the erythrocytes, extra-vascular losses after the first week greatly enhance the development of the anaemia.

In the mouse, as a consequence, maximum depression of lymphocytes, granulocytes, thrombocytes, reticulocytes and erythrocytes generally occurs within 24 hours, 72–96 hours, 9 days, 48 hours and 14 days respectively.

In some animal species—guinea-pig and man—temporary abortive recovery, in particular of the neutrophil granulocytes, has been described. Although normal values are not reached, abortive recovery of granulocytopoiesis in the host may interfere with a correct interpretation of the results of attempted therapy, e.g. bone marrow transplantation.

In the second week following the irradiation, depletion of thrombocytes and leucocytes leads to haemorrhages and septicaemia which terminate the life of the animal. Because of the absence of a cellular reaction against micro-organisms, the septicaemic lesions have a characteristic appearance. At autopsy various organs may be found to be studded with rounded yellowish white foci which on microscopic examination are found to consist of areas of bland necrosis of the parenchymal cells and stroma (Plate IV: 4). Although infiltration with inflammatory cells is absent, masses of bacteria may be seen in the centre of these lesions. In addition, capillaries plugged with bacterial emboli are also present.

Haemorrhages are found in the skin, mucosal and serosal surfaces and in a number of parenchymal organs. The distribution of the haemorrhages is often characteristic of the animal species. Rodents are characterised, for example, by haemorrhages in the pyloric part of the stomach, in the myocardium and in the testes. These are most likely the result of physiological vascular traumata occurring during the

intense muscular activity in these organs*, which are normally repaired by the adherence of thrombocytes at the site of the vascular defect and the subsequent deposition of fibrin. The haemorrhagic diathesis may also induce characteristic lesions in the stomach. Superficial haemorrhages in the mucosa may lead to widespread cystic dilation of glands by compression of the necks of these structures. Sometimes, similar changes may be noted in the large intestine.

Ulcers occur in the oral cavity and the intestinal tract; these may be caused by bacterial infection, haemorrhage or both. Massive haemorrhage may cause ischaemic necrosis by vascular compression. In the monkey large haemorrhages occur in the colon, which lead to mucosal ulceration, total necrosis of the intestinal wall and often perforation to the peritoneal cavity. Microscopically the lesions show desquamation of surface epithelium and necrosis, bacterial infiltration and some haemorrhage of the underlying tissue which is covered with membranes of fibrin. In monkeys, as well as in mice and rats, mucosal necrosis of the colon and caecum, apparently caused by bacterial invasion, is frequently observed (Plate IV: 5). In many cases it is impossible to determine whether the lesion is initiated by bacterial invasion or by haemorrhage. The lesions which have been described are very similar to the necrotic ulcers of the oral mucosa and gastrointestinal tract found in human cases of pure agranulocytosis in which platelet counts are normal. Here, bacterial invasion can be considered to be primarily responsible.

Radiation induced intestinal changes

Radiation doses which cause death from haemopoietic failure do not give rise to intestinal denudation. Significant radiation induced changes may be noted, however, in these cases in the first 4 days after irradiation. It is necessary to describe these lesions in some detail since they must be distinguished from the intestinal lesions due to secondary disease. The latter may be confused with the radiation induced changes in the case of an early severe graft versus host reaction.

Forty-eight hours after irradiation, the crypts in the small intestine are shallow and nuclear pyknosis and fragmentation of crypt cells is present. A small number of crypts are usually cystically dilated and show desquamation of degenerated crypt cells. The height of the in-

* In the case of the testis the vascular traumata are believed to occur as a result of its frequent movements through the inguinal canal, which causes a slight deformation of the organ during the passage.

testinal villi is decreased, and the covering epithelial cells are flattened. Between the affected crypts, varying numbers of regenerated crypts are present, which are lined with a hyperchromatic pseudo-stratified epithelium showing many mitoses. Similar, but less severe changes are found on the following days and recovery is completed on day 6. The large intestine is much less affected, although in the first week some degeneration and an increase in the number of mucoid cells in the crypts may occur. As was mentioned earlier, ulcerations in the colon after the first week are in most cases secondary to haemorrhage and infection.

Recovery of haemopoiesis in bone marrow treated animals

The sequence of changes in the haemopoietic tissues after the intravenous injection of haemopoietic cells has only been studied extensively in irradiated mice. Less complete observations have been reported on the haemopoietic recovery in other species, e.g. rabbits, rats, dogs, monkeys, and human patients.

BONE MARROW

In mice the injection of very large amounts of isologous bone marrow may result in a visible recovery in the recipient's marrow on the 2nd and 3rd day⁴²⁸. Following the administration of the usual amount of isologous or homologous bone marrow, i.e. 10^6 and 10^7 cells per mouse respectively, recovery may be noted on the 4th day at the earliest⁴⁴⁹. Between the fat cells and the dilated sinusoids of the aplastic bone marrow, proliferation of reticular cells and large stem cells—haemocytoblasts—has occurred. (Plate IV: 6). On the 5th day cellular bone marrow is usually found, the haemopoietic elements still consisting mainly of stem cells of all cell lines (Plate IV: 7). During the following days, maturation of the marrow continues and the composition of the bone marrow appears to be normal on day 7. Hypercellularity of the bone marrow, caused by stem cell hyperplasia, is often seen during the first month following the recovery and may persist after that time in animals treated with homologous or heterologous bone marrow.

Simultaneously with the marrow regeneration, foci of extramedullary haemopoiesis appear in the spleen, liver, and lymph nodes. In the first month following treatment the spleen may be greatly enlarged due to extensive infiltration of the red pulp with haemopoietic cells (Plate IV: 8). After that time extramedullary haemopoiesis

diminishes and towards the 6th week, in mice treated with isologous bone marrow, it has returned to a normal level. Persistence of excessive extramedullary haemopoiesis is usually seen, however, in mice treated with homologous or heterologous bone marrow (Plate IV: 8).

Information on bone marrow histology is available for a number of other recipient species. In rabbits treated with homologous bone marrow, repopulation has been followed up and, in those animals which suffered from secondary disease, hyperplasia was found to be present³²⁵. In rats and guinea pigs examined approximately 14 days after isologous bone marrow transplantation the appearance of the bone marrow had returned to normal⁴⁴⁵. In rats treated with homologous bone marrow, bone marrow recovery started on day 6. The histological pattern of regeneration in the following days was similar to that in mice. However, in many rats relatively hypocellular or even acellular areas persisted in an otherwise normally matured marrow^{14, 18}. In monkeys⁴⁴⁶ early repopulation of the bone marrow has been noted on day 6 and 7 following transplantation of autologous or homologous marrow. These investigations have suggested that, following cell doses of comparable effectiveness with respect to radiation protection, bone marrow regeneration in monkeys occurs later than in mice. Repopulation of the bone marrow has also been shown to occur in irradiated patients after treatment with homologous bone marrow²⁶³, but the time of onset of repopulation and its completion after the bone marrow transfusion has not yet been exactly established (Plate IV: 9).

LYMPHATIC TISSUES

The time and the extent of the regeneration of the lymphatic tissues is dependent on both the number of lymphoid cells contained in the injected cell suspension and also the host donor combination.

Following the administration of bone marrow only, regeneration is first seen on the 6th day after autologous treatment (monkeys), isologous combinations (mice) and in homologous and heterologous combinations (mice and monkeys) (Plates IV: 10 and 17). Compared with mice, the repopulation of lymphatic tissue in monkeys is relatively early if the time of bone marrow recovery is taken into account. This could be one of the reasons for the more severe character of secondary disease in monkeys, as has been mentioned in Chapter III.

At the end of the first week collections of large immature lymphoid cells, presumably lymphoblasts, appear between the reticular cells of

the stromal tissue in the follicles of the spleen, the cortex of the lymph nodes and thymus and the remnants of the accumulations of the lymphatic tissue in the intestinal tract. Mitotic figures are seen in these areas of regeneration. In the days following, the number of lymphoid cells increases in both autologous and isologous combinations. Mature lymphocytes appear and follicle formation occurs. Advanced regeneration is found in the second week and in the course of the 3rd and the 4th week the lymphatic tissues attain a normal histological appearance (Plate IV: 11).

In a number of homologous or parent to F_1 combinations in mice, complete regeneration of the lymphatic tissues similarly occurs in about a month. In other homologous or heterologous combinations in mice and in homologous combinations in rats, rabbits, monkeys, and men, the initial regeneration is followed by secondary changes which will be discussed in the section dealing with secondary disease.

PERIPHERAL BLOOD

The peripheral blood changes which follow irradiation and bone marrow transplantation have been studied in mice, monkeys, and men.

The destruction of the host's bone marrow is reflected in the gradual disappearance of the mature elements in the blood, similar to that seen in non-treated irradiated animals.

The take and proliferation of the bone marrow graft is indicated by the reappearance of reticulocytes as early as the 5th day, followed by reticulocytosis in the 2nd and 3rd week. The neutrophil count increases after the 5th day, followed by a rise of the thrombocyte count on the 9th day and of the mononuclear cells at the end of the 2nd week. After treatment with isologous bone marrow the peripheral blood cell count is restored to normal by the end of the 4th week, the values of the mononuclear cells being depressed the longest¹⁴⁹.

In monkeys recovery of the peripheral blood elements to their normal levels occurred later than in mice and, moreover, the time of recovery was found to be more variable (1-3 weeks). This was probably due either to differences in the number of bone marrow cells injected in these particular experiments or to a slower proliferation rate of the grafted cells in monkeys.

In the human cases in which the irradiation factors were carefully controlled and bone marrow grafting proved to be successful, recovery of the peripheral blood count occurred after about 13-20 days²⁶³.

In the recovery phase many immature cells appeared in the peripheral blood. Myelocytes, erythroblasts, large erythrocytes and large basophilic thrombocytes, were noted as transient features in the smears.

In comparison with animals treated with isologous bone marrow, those treated with homologous or heterologous bone marrow showed abnormalities of the peripheral blood count during or following the recovery phase; these abnormalities will be discussed in the next section.

Graft rejection in homologous and heterologous chimaeras

The cause of the delayed death of animals treated with foreign bone marrow, in contrast to the almost uniform survival of those treated with isologous or autologous marrow, has been an important issue for some time.

As has been mentioned earlier, two opposing explanations were postulated: a graft versus host or a host versus graft reaction. A follow-up study of lethally irradiated mice treated with homologous or heterologous bone marrow showed that particularly after irradiation in the lower lethal dose range, either of these immunological reactions might be responsible for delayed death of the chimaeras⁴⁴⁹.

The proportion of animals suffering from a graft rejection, or failure of the graft to take, varies with both the radiation dose and the host donor combination, as discussed in Chapter III. Death from a delayed rejection of the marrow graft after an initial take usually occurs earlier (14–20) days than death from a graft versus host reaction (after the 20th day). The two modes of death may, however, overlap in time or, as has been found in monkeys, may even be present simultaneously.

THE "SPLENIC WHITE PULP REACTION"

It has to be assumed, therefore, that even after lethal radiation doses the immunological reactivity of the host is not completely suppressed. A histological counterpart of such immunological activity of the host was described by Congdon⁹⁵. This reaction, designated as the splenic white pulp reaction, was found to occur in lethally irradiated mice. These histological changes will be described in some detail, since they may reflect the ability of the host to reject a foreign graft after irradiation in the lower lethal dose range.

The reaction was observed in the first 3 days following bone

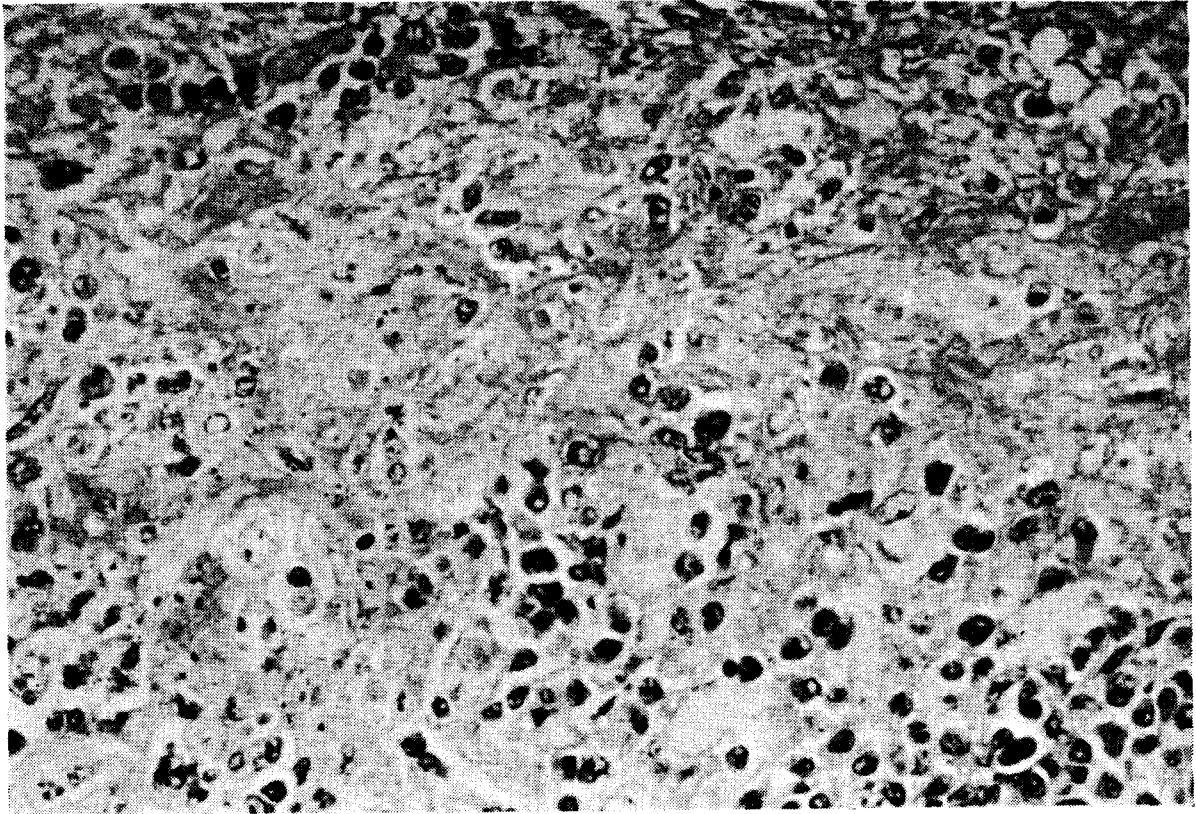


PLATE IV: 13. Fibrinoid necrosis in red pulp of spleen in an irradiated rat rejecting a homologous bone marrow graft at 9 days. Deposition of finely fibrillar fibrinoid substance and disintegrated cells in centre of picture. Note surrounding normal myeloid cells. (HE). Magnification $\times 300$

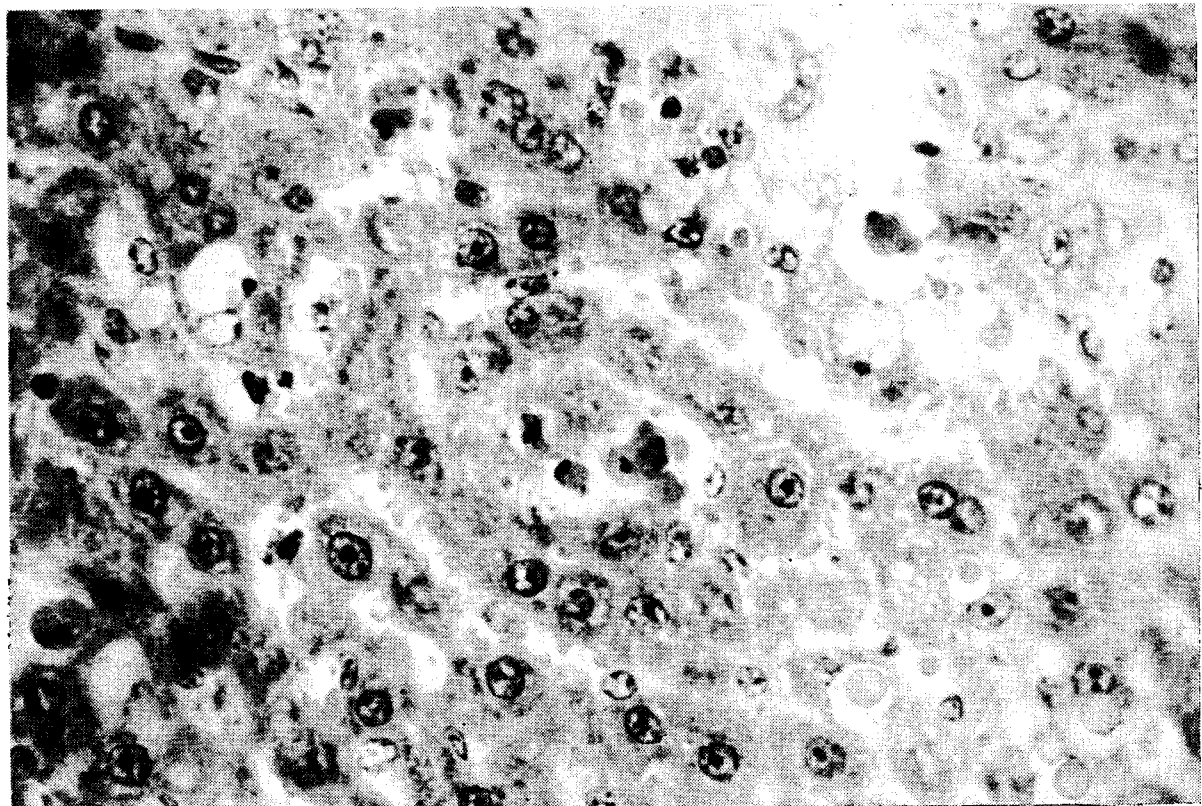


PLATE IV: 14. Isolated disintegration of liver cells in lethally irradiated rat dying 9 days after treatment with homologous spleen cells. (HE). Magnification $\times 300$

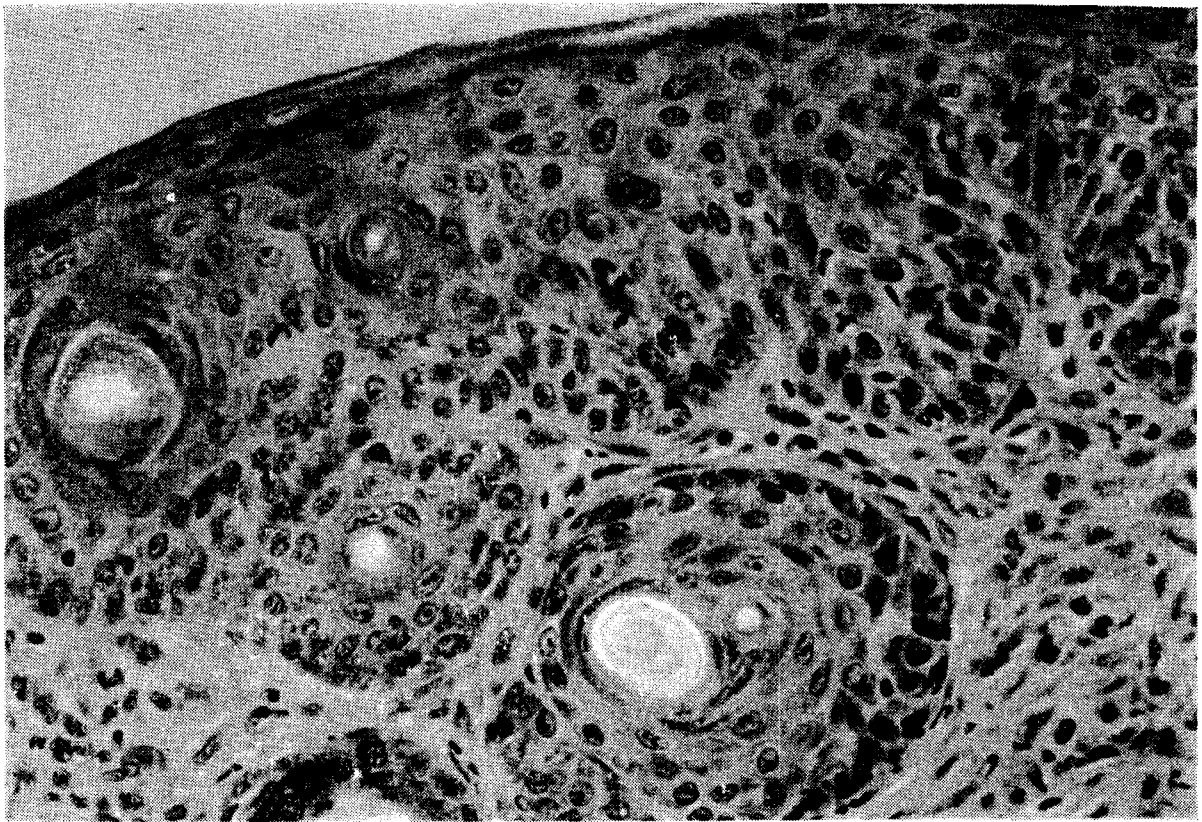


PLATE IV: 15. Hyperplastic change (acanthosis) of epidermis and hair follicles in 8-month old homologous mouse chimaera. Note slight infiltration of dermis with lymphoid cells and histiocytes. (HE). Magnification $\times 300$

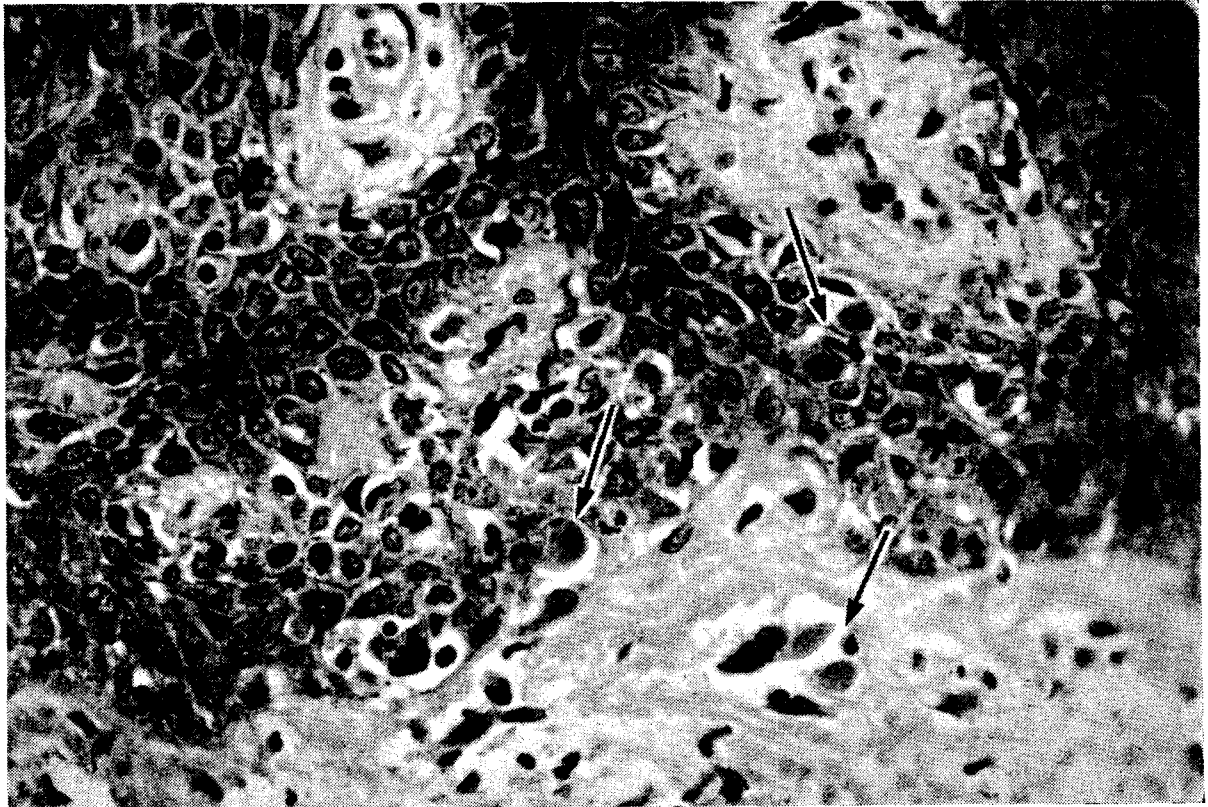


PLATE IV: 16. Skin biopsy of leukemia patient suffering from severe secondary disease after irradiation with 800 r and treatment with pooled bone marrow of 6 donors. The epidermis is infiltrated by lymphoid cells. In the immediate surrounding of these cells the epithelial cells display degenerative changes, most pronounced being a vacuolisation of the cytoplasm. Some cells are necrotic: rounded homogeneously eosinophilic cell remnants indicated by arrows (dyskeratosis). (HE). Magnification $\times 300$

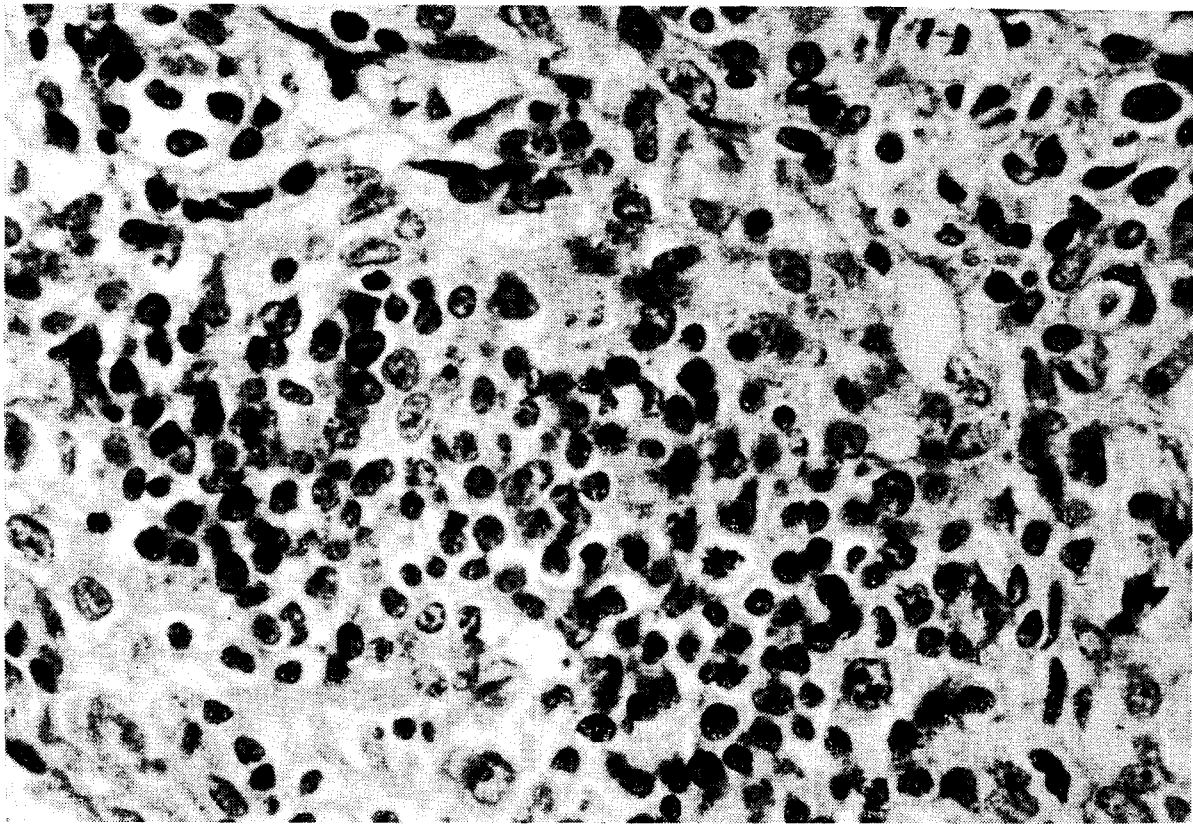


PLATE IV: 17. Early regeneration of lymphatic tissue in lymph node cortex of homologous mouse chimaera on day 7. Note focal collection of lymphoblasts and lymphocytes. Several mitoses are present. (HE). Magnification $\times 480$

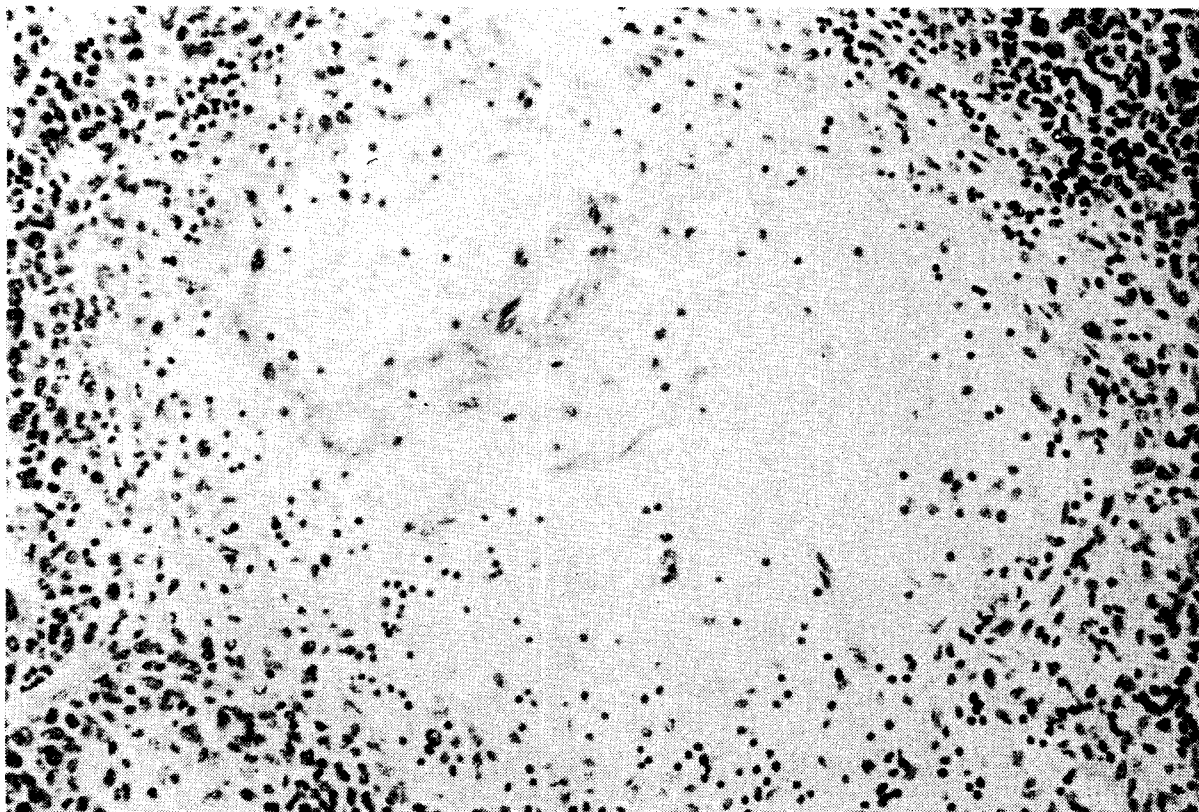


PLATE IV: 18. Complete atrophy of lymphatic tissue surrounding splenic arteriole in spleen of homologous mouse chimaera on day 44. Surrounding the empty follicle are many haemopoietic cells. (HE.) Magnification $\times 190$

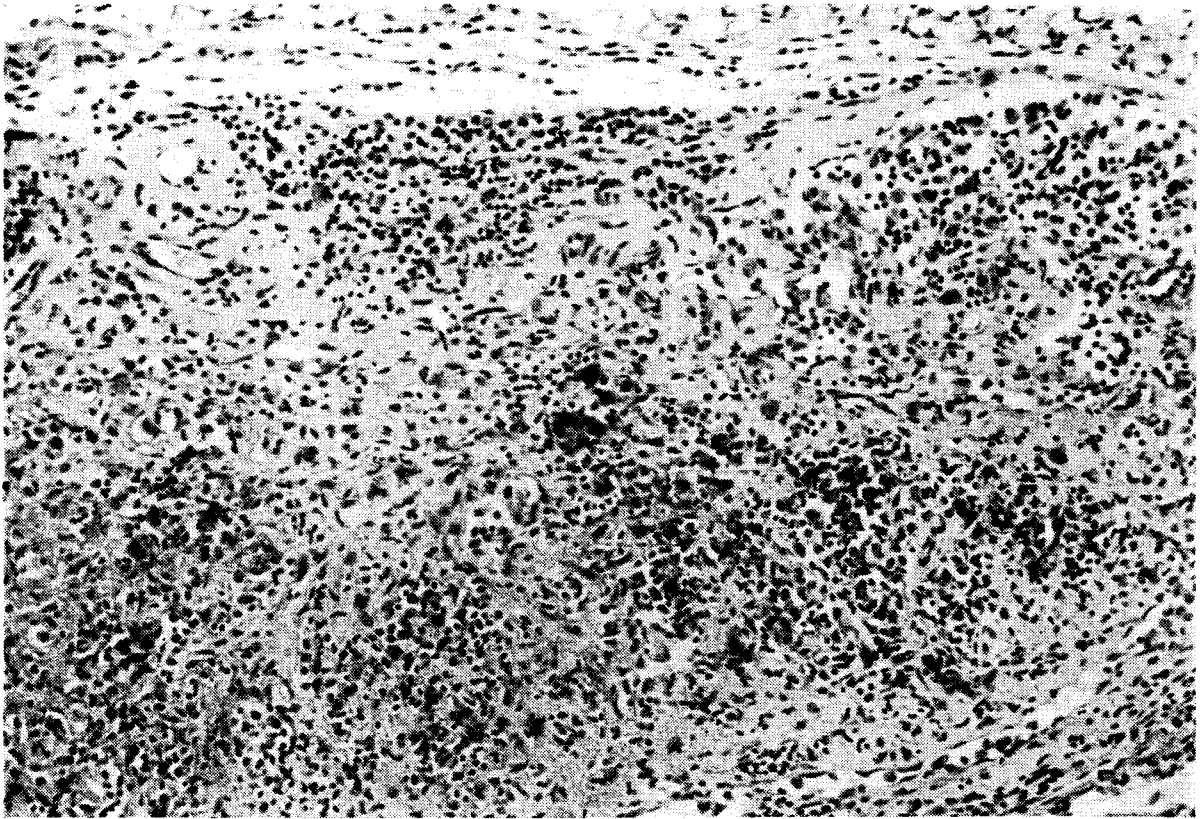


PLATE IV: 19. Severe atrophy of lymph node of 6-week old heterologous (rat bone marrow treated) mouse chimaera. Note absence of lymphatic follicles, scarcity of lymphoid cells and fibrosis. (HE). Magnification $\times 120$




Plate IV: 20. Complete regeneration of lymphatic tissue of spleen in 79-day old homologous mouse chimaera. The host-donor combination in this case generally produces severe secondary disease (CBA host, C57BL donor). A large lymphatic follicle is present in upper left corner. (HE). Magnification $\times 120$

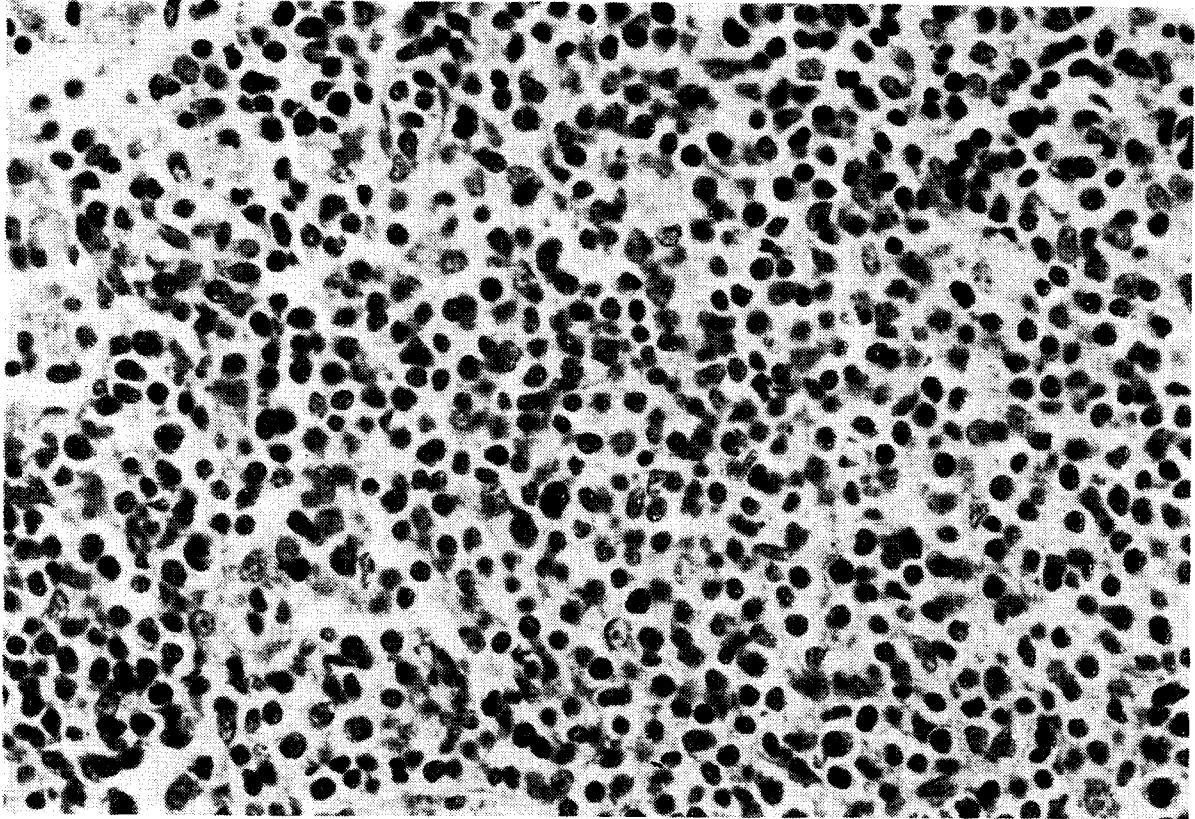


PLATE IV: 21. Intense lymphopoeitic activity in mesenteric lymph node of monkey that died on day 7 following treatment with homologous bone marrow. The animal suffered from severe secondary disease. Note many lymphoblasts, medium-sized and small lymphocytes and several mitoses. (HE). Magnification $\times 300$

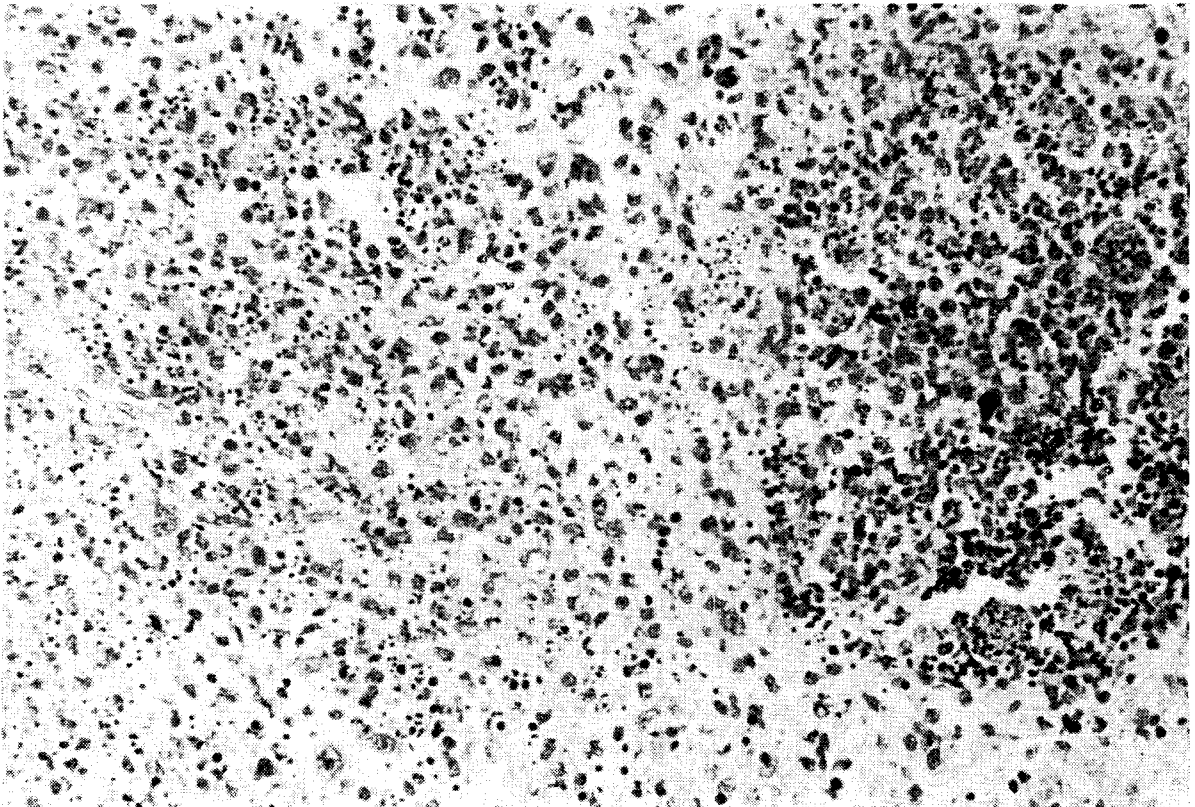


PLATE IV: 22. Massive karyorrhexis of lymphoid cells in mesenteric lymph node of homologous monkey chimaera on day 14. Note follicular remnant on right side of picture. The stromal cells appear unaffected. (HE). Magnification $\times 100$

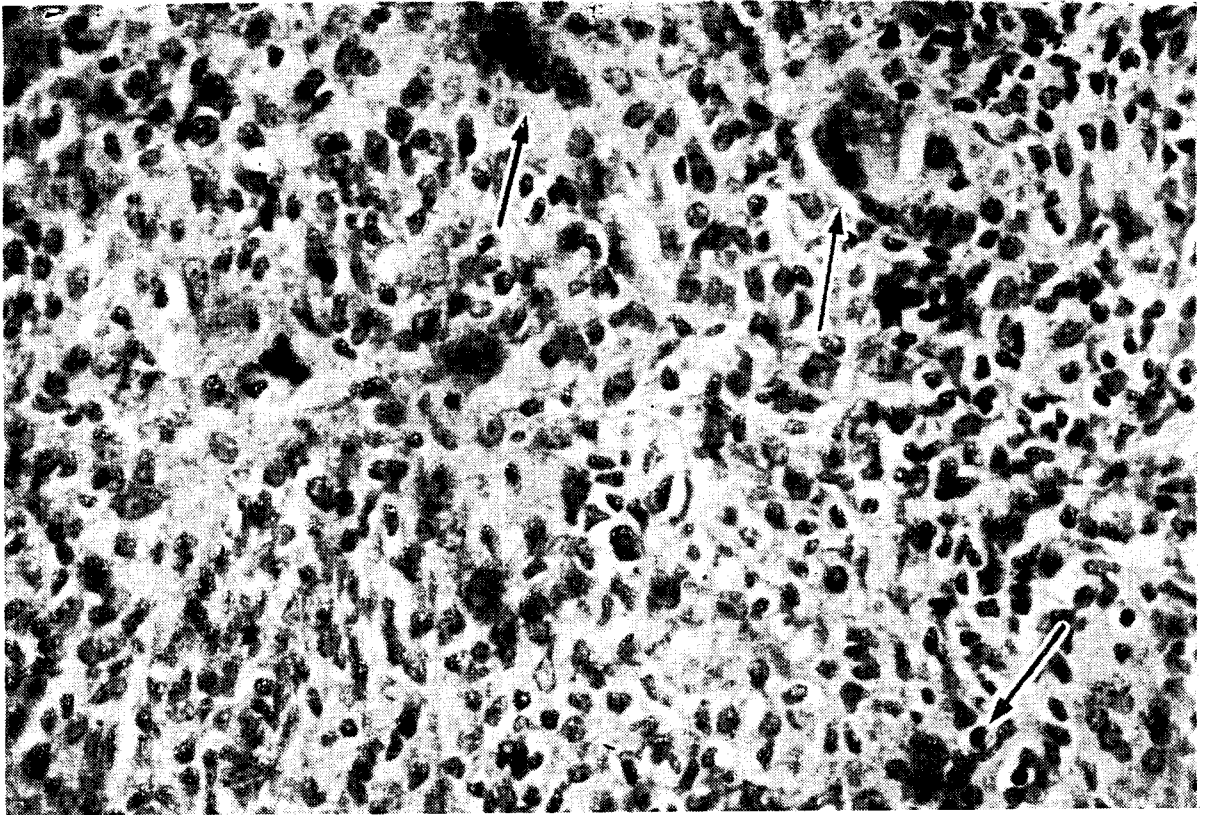


PLATE IV: 23. Granulomatous reaction in lymph node of 24-day old homologous mouse chimaera. Note presence of many histiocytes (epithelioid cells) and several multinuclear giant cells of histiocytic origin (arrows). (HE). Magnification $\times 300$

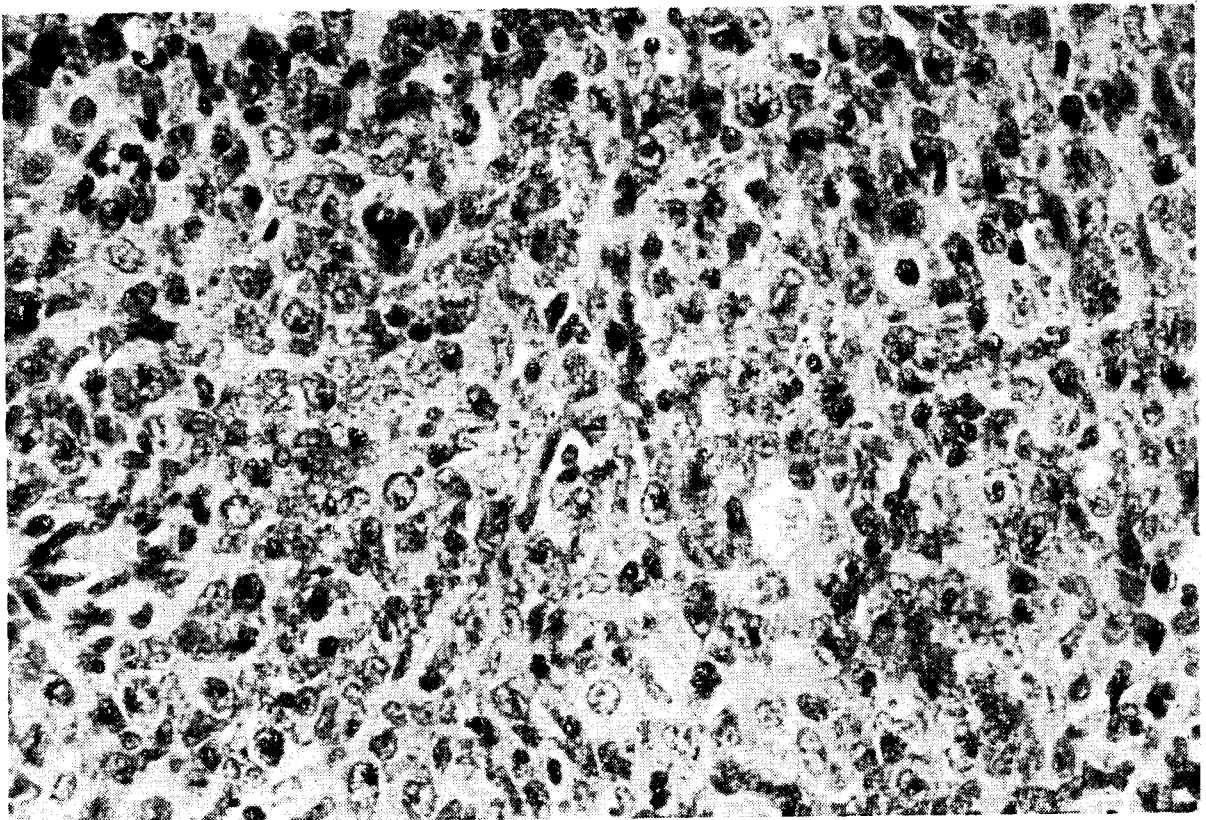


PLATE IV: 24. Intense lymphopoietic activity in mesenteric lymph node of CBA mouse on day 4 after irradiation with 800 r and treatment with 10^6 C57BL lymph node cells. Many lymphoblasts and medium-sized lymphocytes are seen, while a few small lymphocytes are also present. Note several mitoses. Compare with Plate IV: 21 of a homologous monkey chimaera, treated with bone marrow

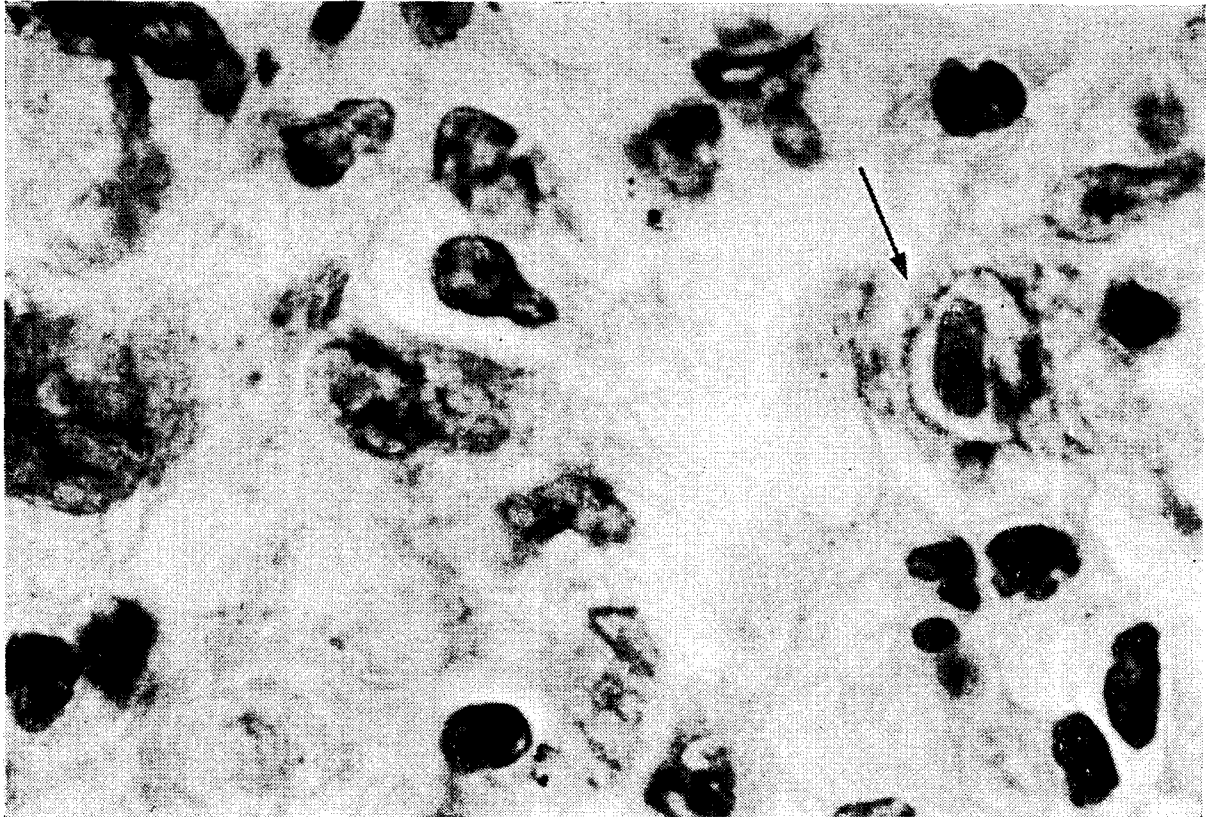


PLATE IV: 25. Interstitial pneumonitis of probable viral aetiology in homologous monkey chimaera (47 days). Large nuclear inclusion body in alveolar cell indicated by arrow. (HE). Magnification $\times 1200$

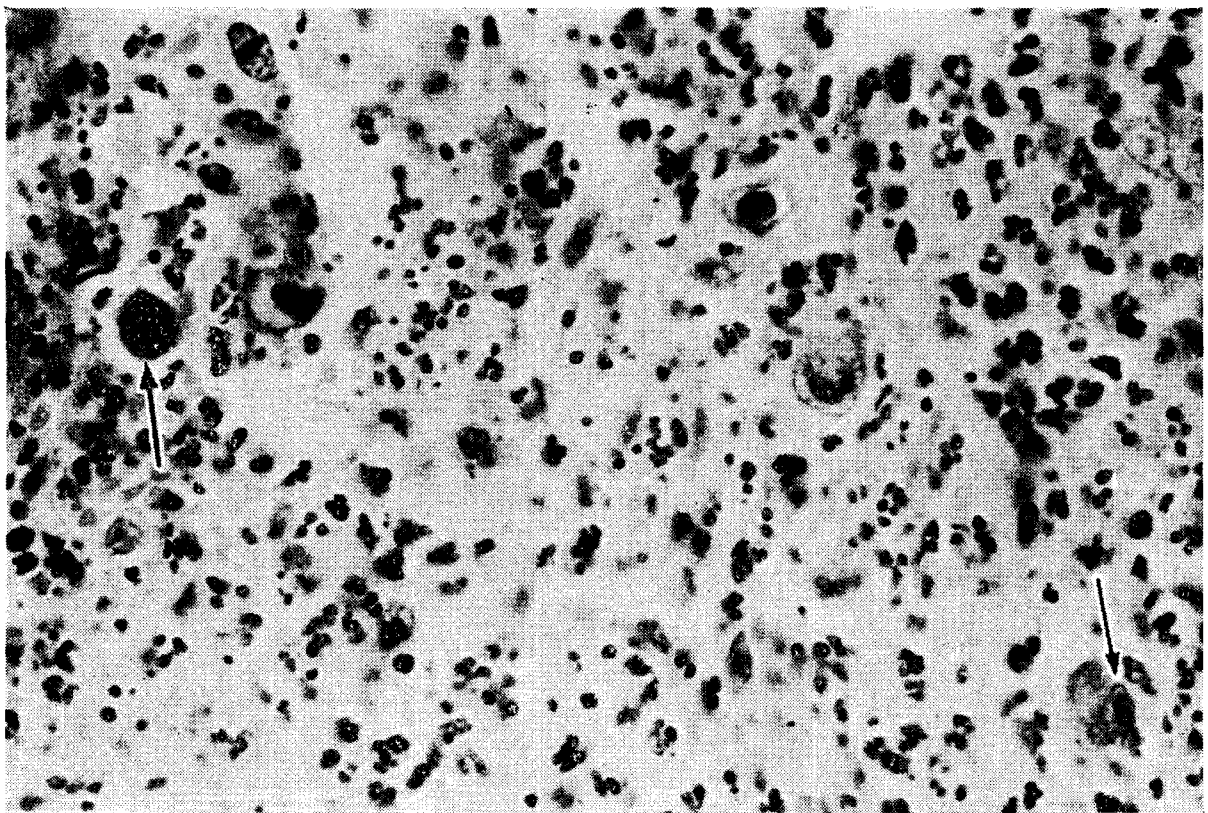


PLATE IV: 26. Ulcerating lesion in colonic mucosa of homologous monkey chimaera (27 days) showing many large cells with nuclear inclusion bodies. Two of these are indicated by arrows. (HE) Magnification $\times 480$

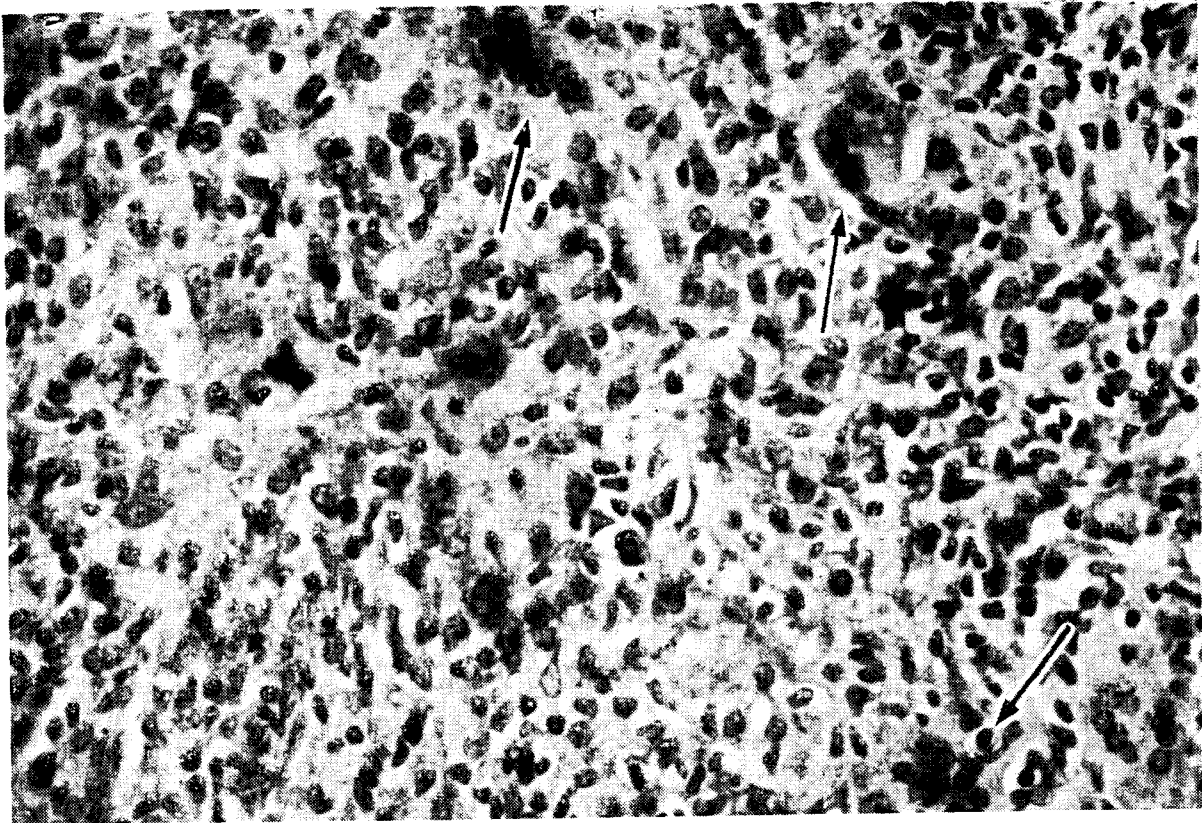


PLATE IV: 23. Granulomatous reaction in lymph node of 24-day old homologous mouse chimaera. Note presence of many histiocytes (epithelioid cells) and several multinuclear giant cells of histiocytic origin (arrows). (HE). Magnification $\times 300$

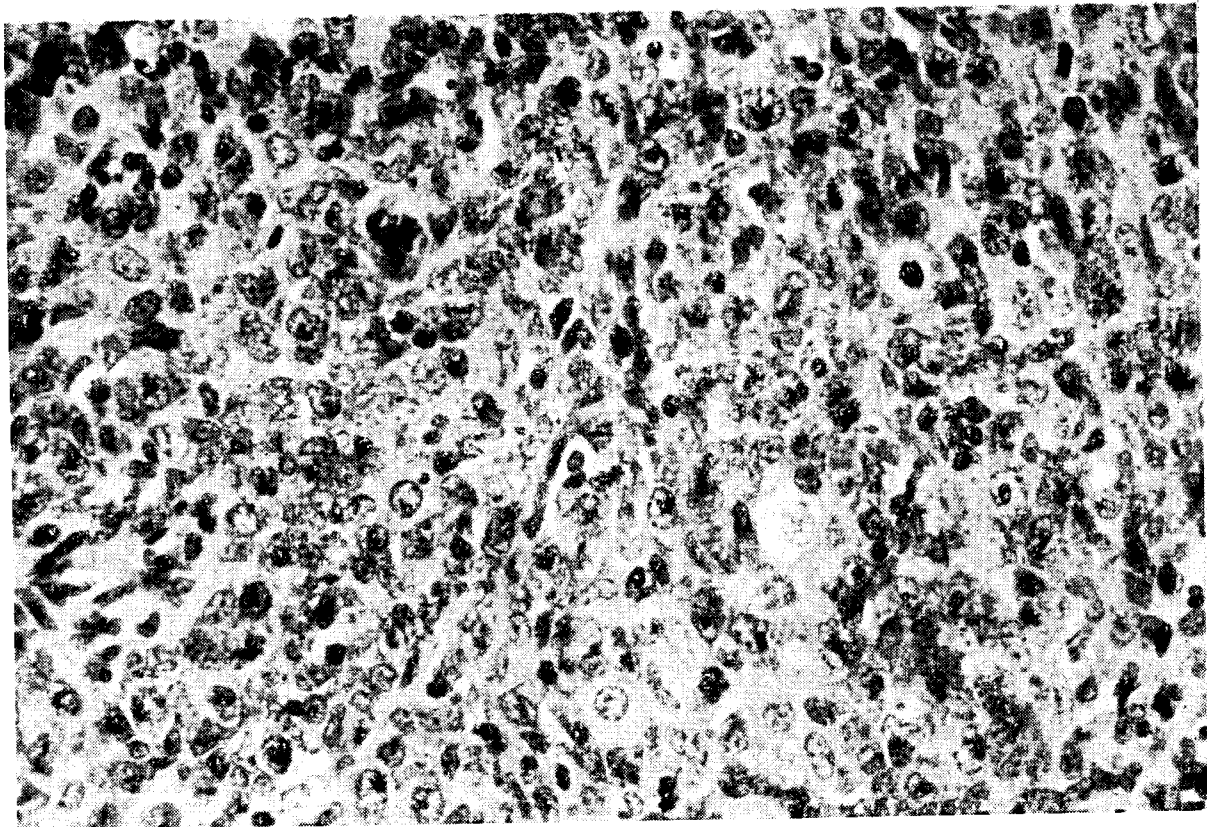


PLATE IV: 24. Intense lymphopoietic activity in mesenteric lymph node of CBA mouse on day 4 after irradiation with 800 r and treatment with 10^6 C57BL lymph node cells. Many lymphoblasts and medium-sized lymphocytes are seen, while a few small lymphocytes are also present. Note several mitoses. Compare with Plate IV: 21 of a homologous monkey chimaera, treated with bone marrow

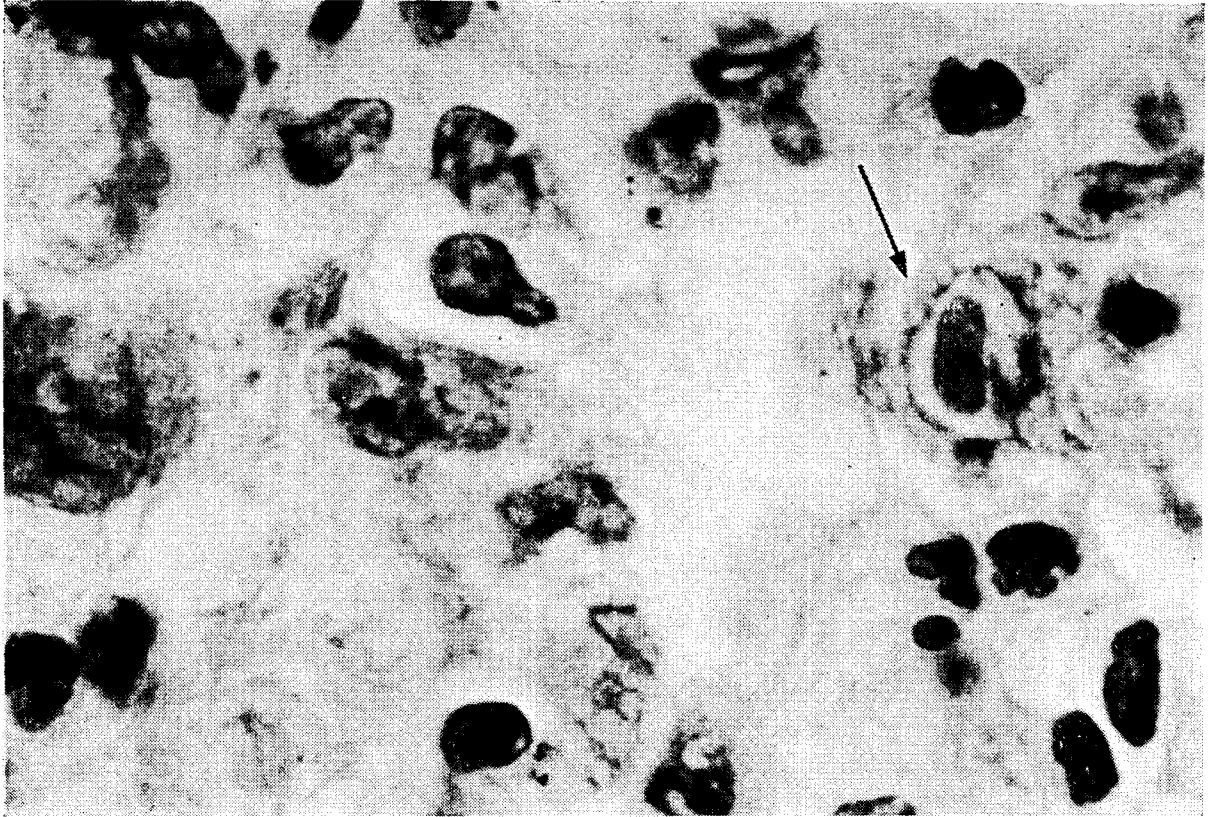


PLATE IV: 25. Interstitial pneumonitis of probable viral aetiology in homologous monkey chimaera (47 days). Large nuclear inclusion body in alveolar cell indicated by arrow. (HE). Magnification $\times 1200$

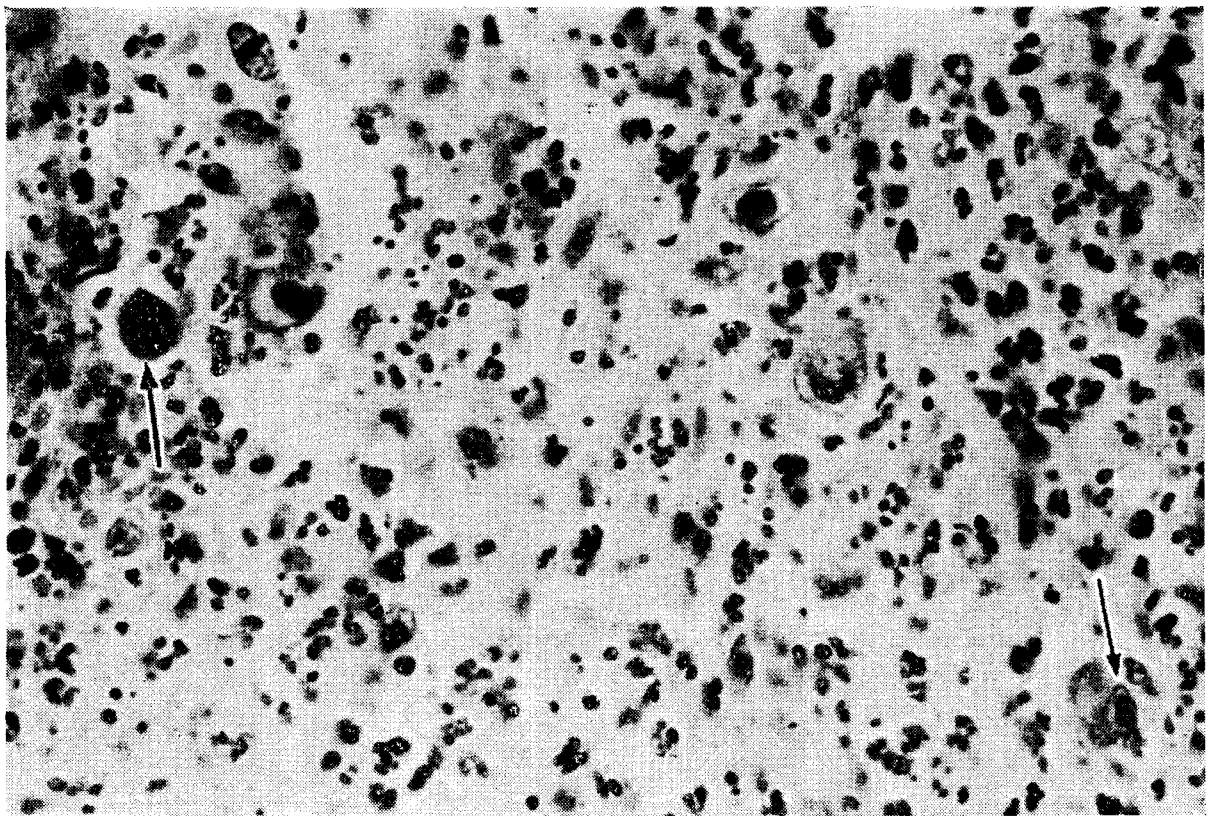


PLATE IV: 26. Ulcerating lesion in colonic mucosa of homologous monkey chimaera (27 days) showing many large cells with nuclear inclusion bodies. Two of these are indicated by arrows. (HE) Magnification $\times 480$

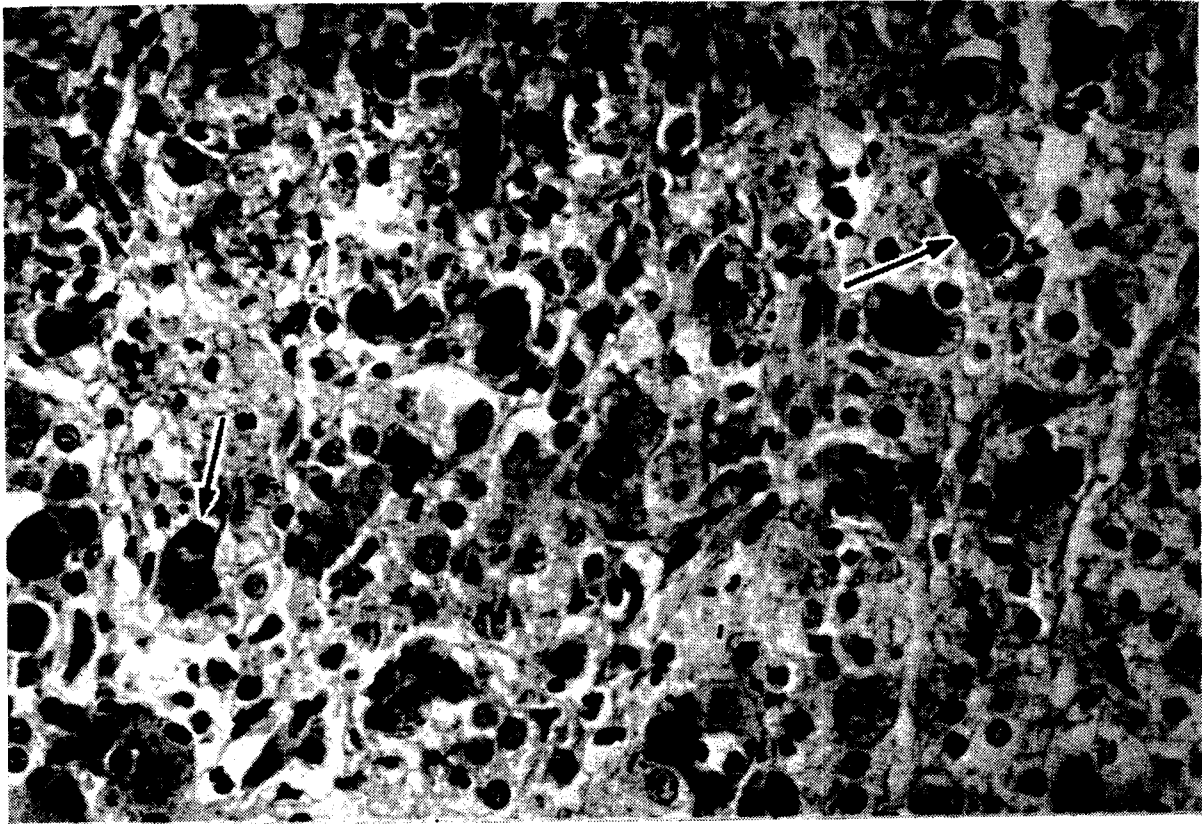


PLATE IV: 27. Focal necrosis of adrenal cortex in leukaemic child, which died 43 days after irradiation with 890 r and treatment with bone marrow from his own mother. Several giant cells with prominent nuclear inclusion bodies are present; two of these are indicated by arrows. Photograph from Mathé *et al.* (1960)²⁶³. (HE) Magnification $\times 300$




PLATE IV: 28. Shedding of the mucosa of colon (a), ileum (b) and jejunum (c) in homologous monkey chimaera (13 days) with severe secondary disease. Greyish-green membranes of sloughed mucosa project into the lumen. The duodenum (d) appears normal.

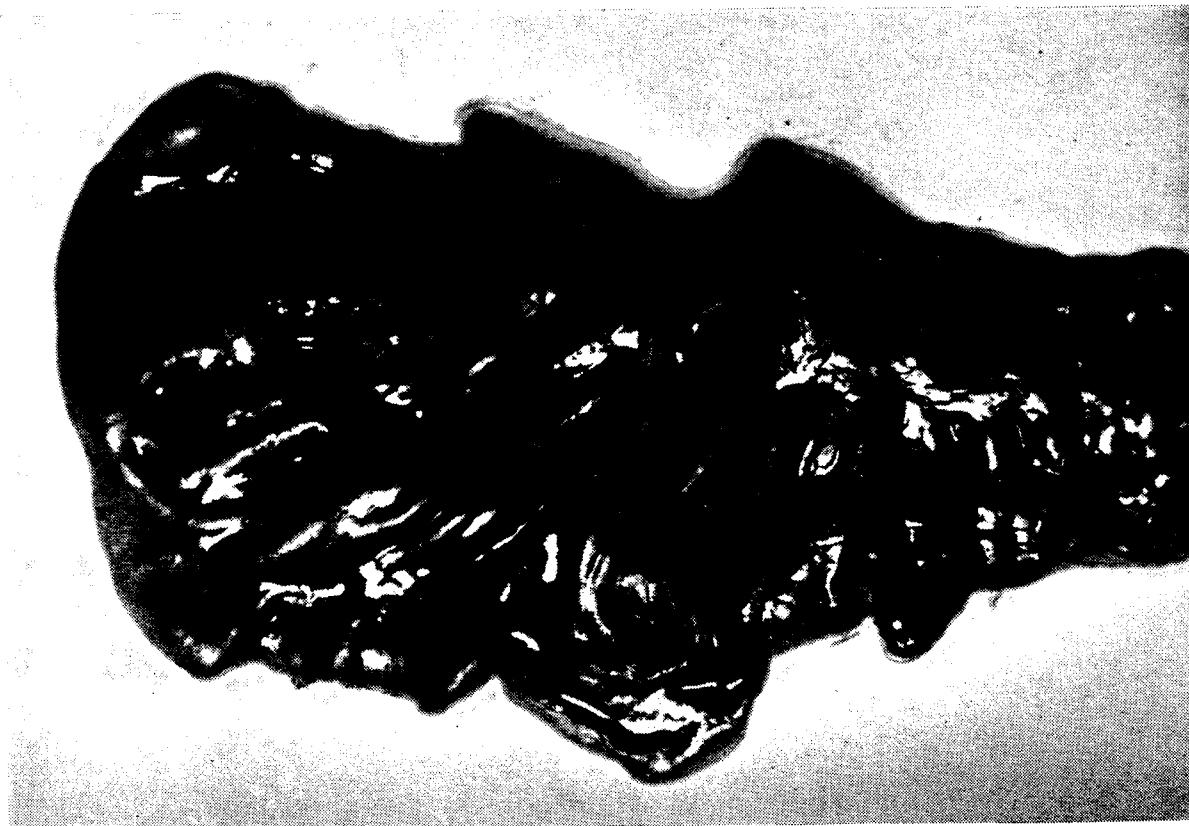


PLATE IV: 29. Atrophy of mucosa of cecum and ascending colon in homologous monkey chimaera (19 days). Note smooth glistening surface of mucosa and unusual prominence of lymphatic follicles, appearing as greyish-black dots.

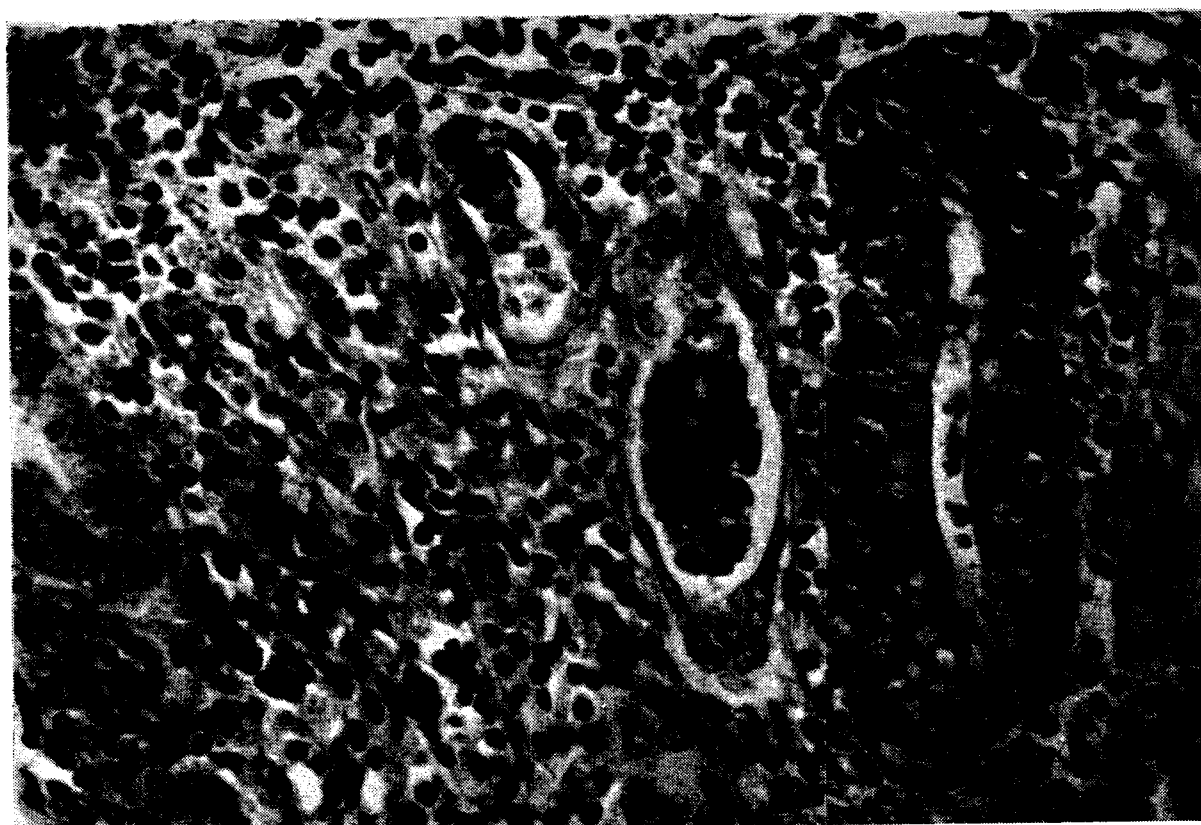


PLATE IV: 30. Acute disintegration of the crypts in colon of homologous monkey chimaera, that died on day 7. The mucosa is heavily infiltrated with lymphocytes which have also penetrated the crypts. Note severe karyorrhexis in the crypts and two crypts in centre distended with desquamated necrotic cells. (HE). Magnification $\times 300$

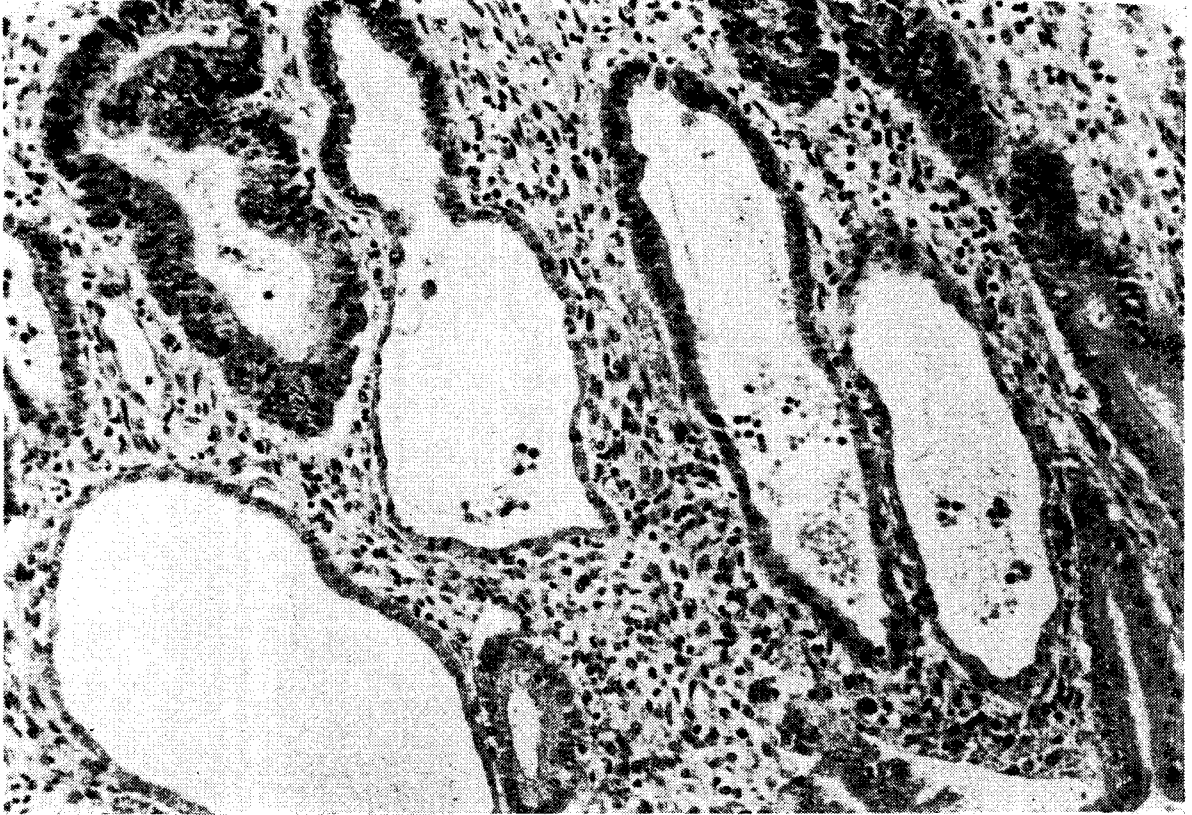

PLATE IV: 31. Cystic degeneration of crypts in colon of homologous monkey chimaera at day 26. The dilated atrophic crypts are lined with a single layer of flattened epithelium. Hyperplastic crypt in upper left corner. (HE). Magnification $\times 120$

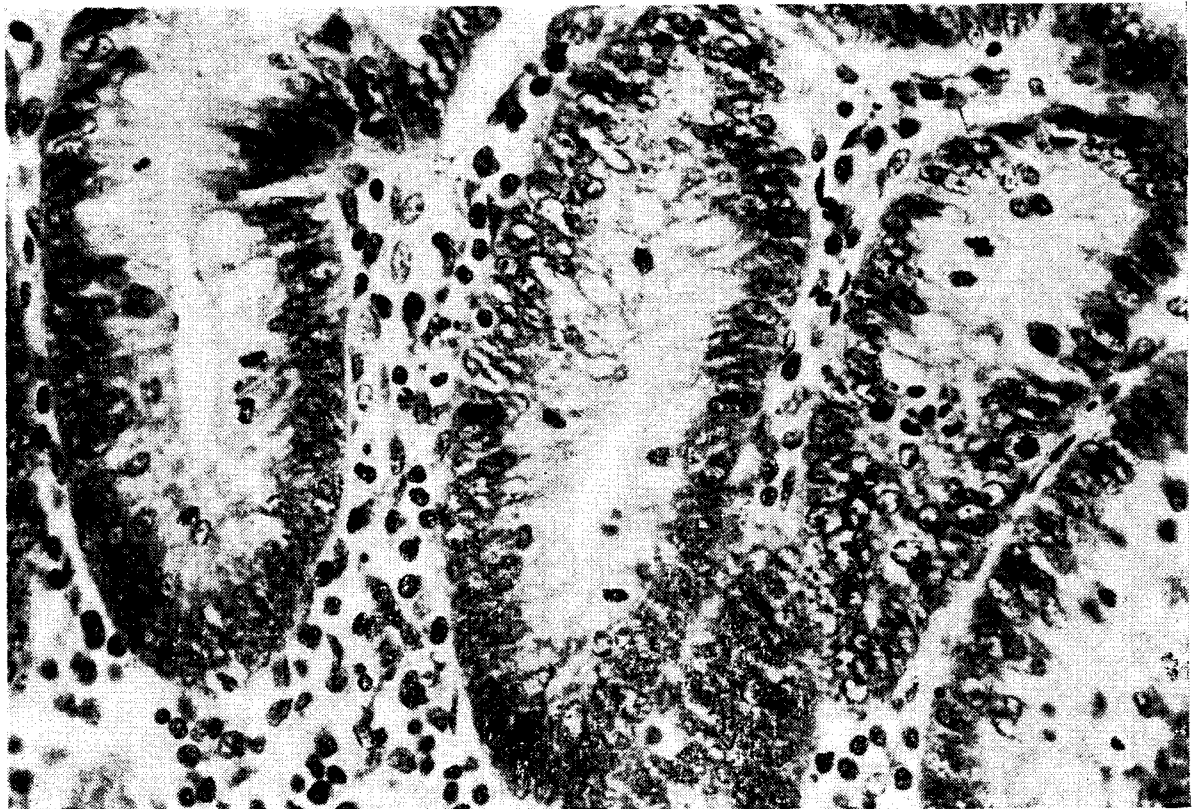


PLATE IV: 32. Hyperplastic crypts in colon of homologous monkey chimaera (same as in Plate IV: 30). The crypts are lined with a tall darkly staining epithelium showing many mitoses. (HE). Magnification $\times 300$

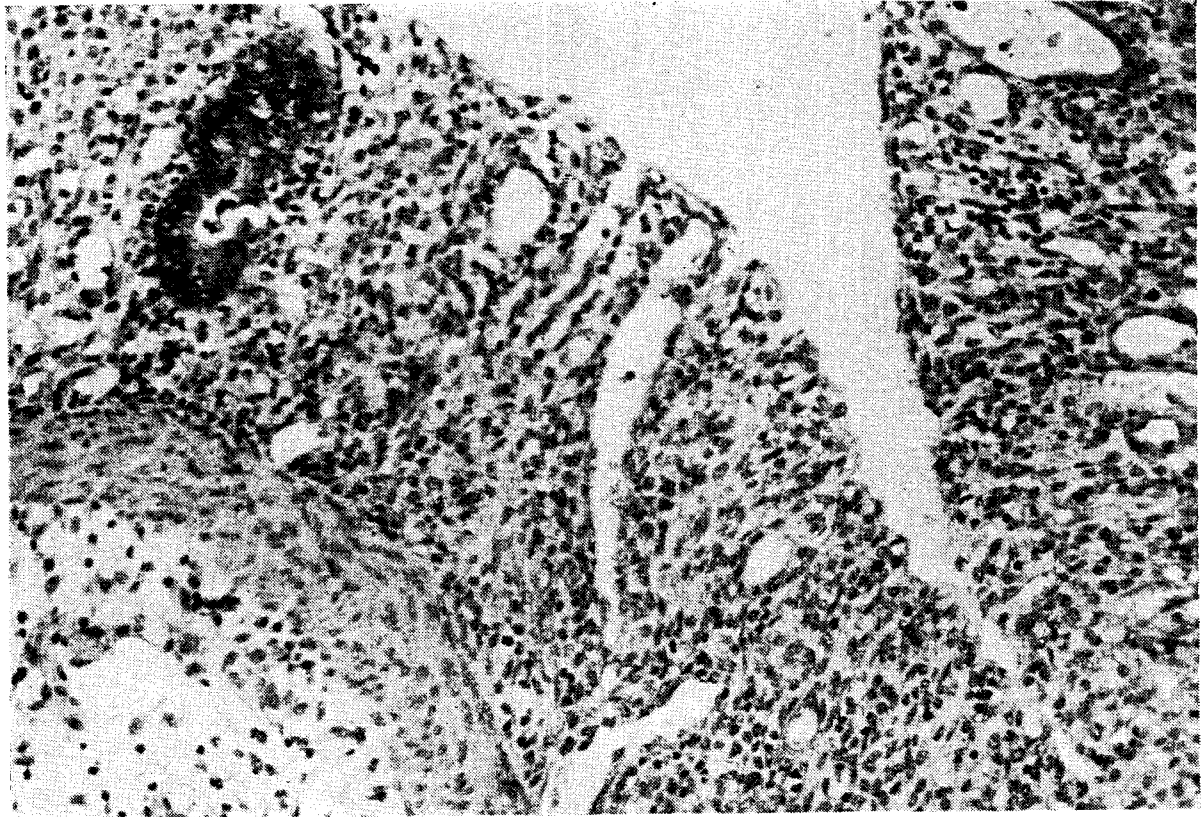


PLATE IV: 33. Denudation of colonic mucosa in homologous monkey chimaera. Note absence of surface epithelium and almost total loss of crypts. The stromal cells of the mucosa appear normal. (HE). Magnification $\times 120$

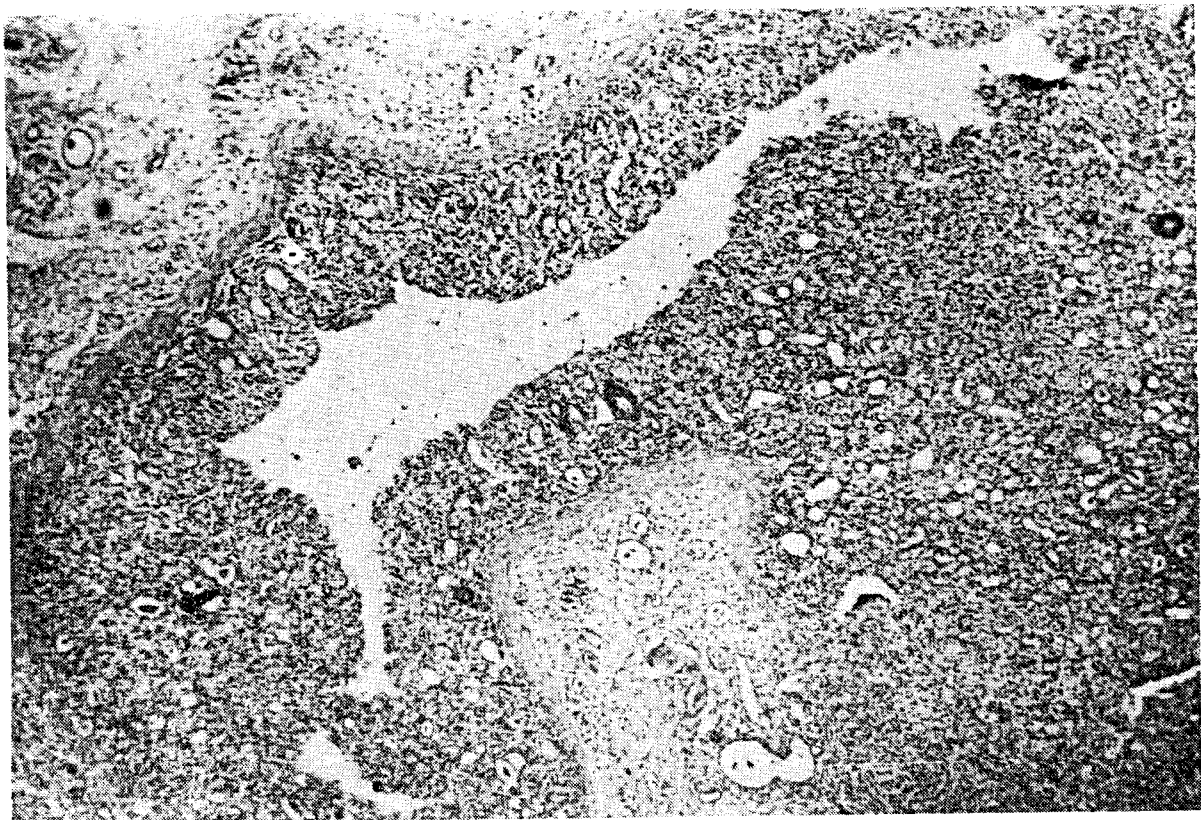


PLATE IV: 34. Near total loss of surface and crypt epithelium in ileum of homologous monkey chimaera (same animal as in Plate IV: 33). (HE). Magnification $\times 30$

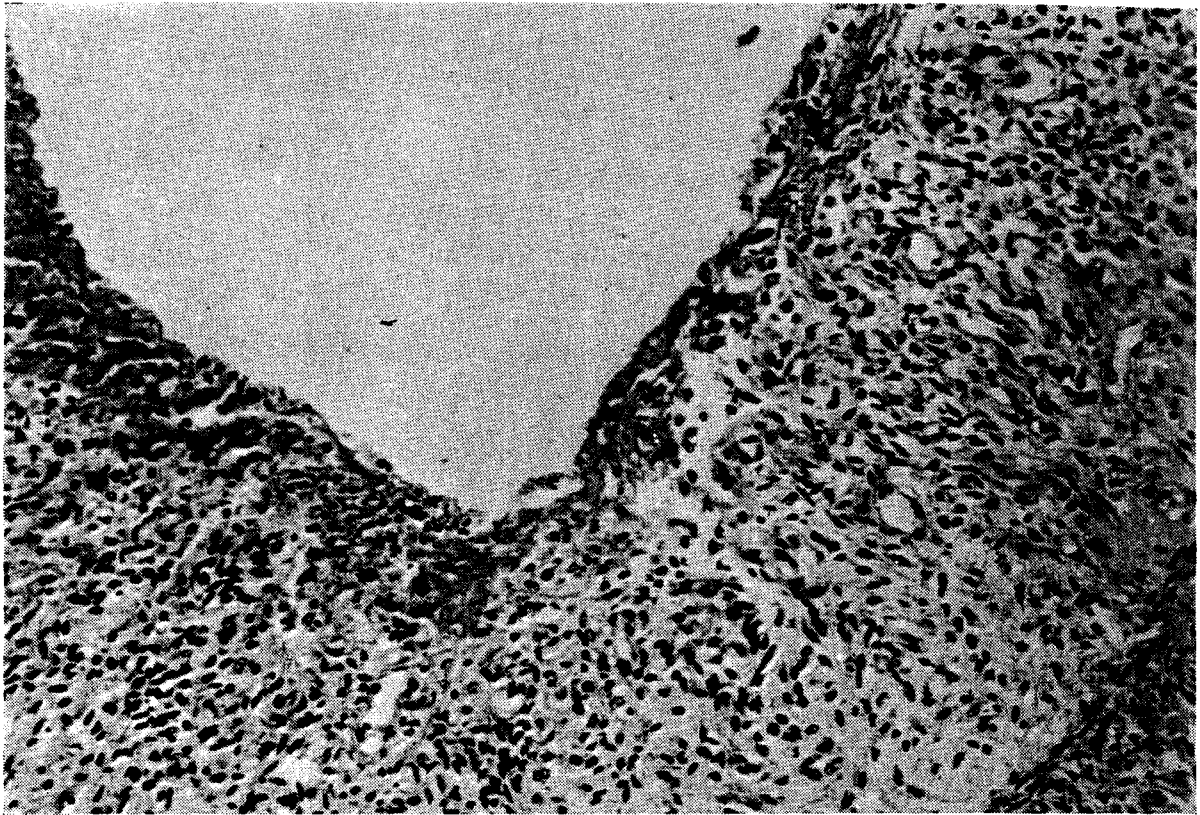


PLATE IV: 35. Total denudation of mucosa of ileum in a human radiation chimaera, transplanted with bone marrow of his mother, dying 43 days following the irradiation. Surface epithelium and crypts are absent. The substantia propria is covered with a thin layer of fibrin. (HE). Magnification $\times 120$

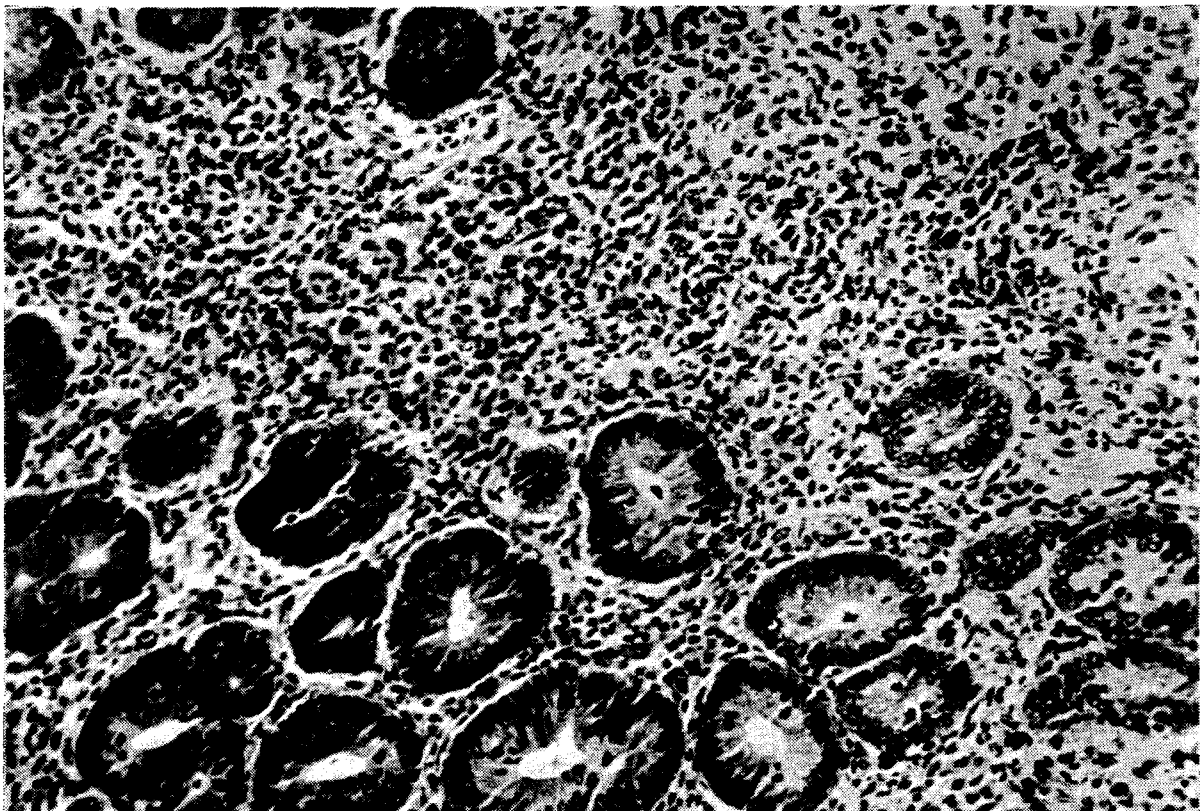


PLATE IV: 36. Chronic colitis in a rat \rightarrow mouse chimaera 44 days after bone marrow transplantation. A dense infiltration of polynuclear leucocytes, plasma cells and lymphocytes separates the crypts, some of which are hyperplastic. (HE). Magnification $\times 190$

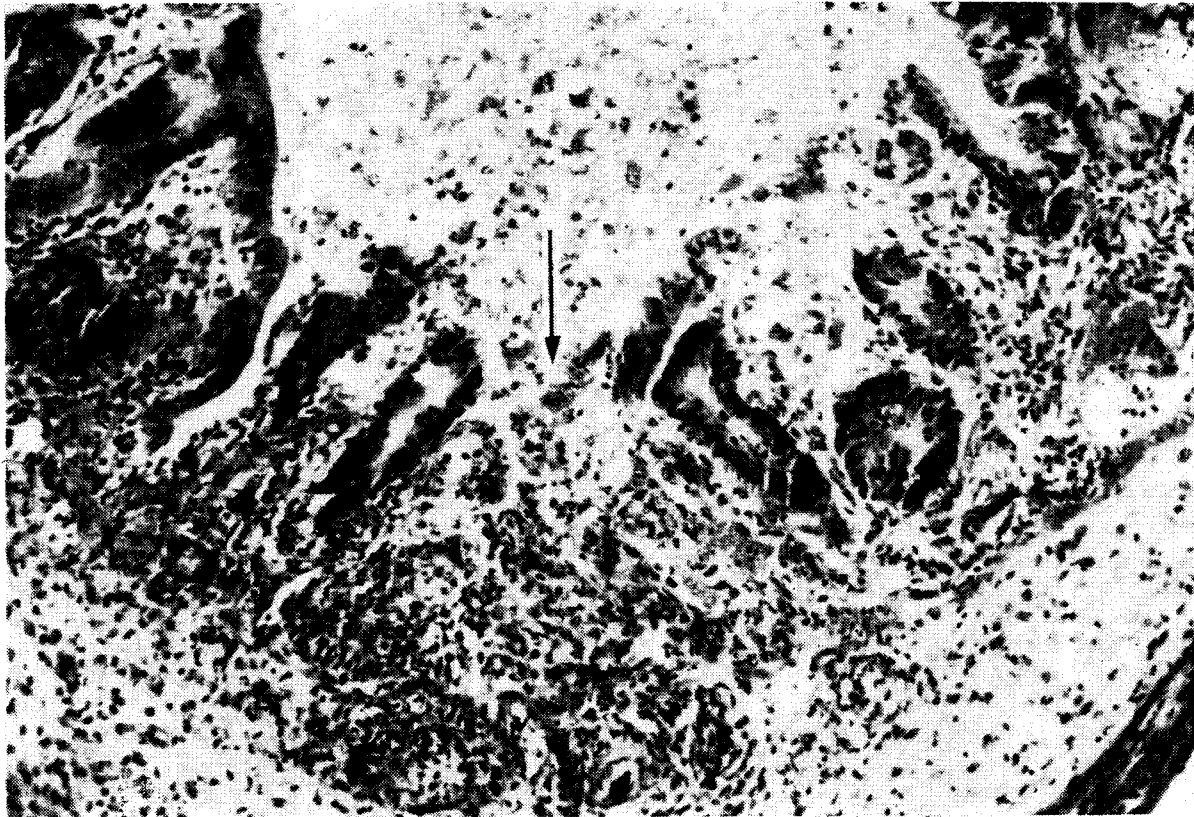


PLATE IV: 37. Chronic colitis in rat \rightarrow mouse chimaera on day 35. The inflammatory infiltrate spreads through the submucosa into the muscular coat. There is pronounced oedema of the submucosa. Note destruction of crypts and small area of ulceration (arrow). (HE). Magnification $\times 120$

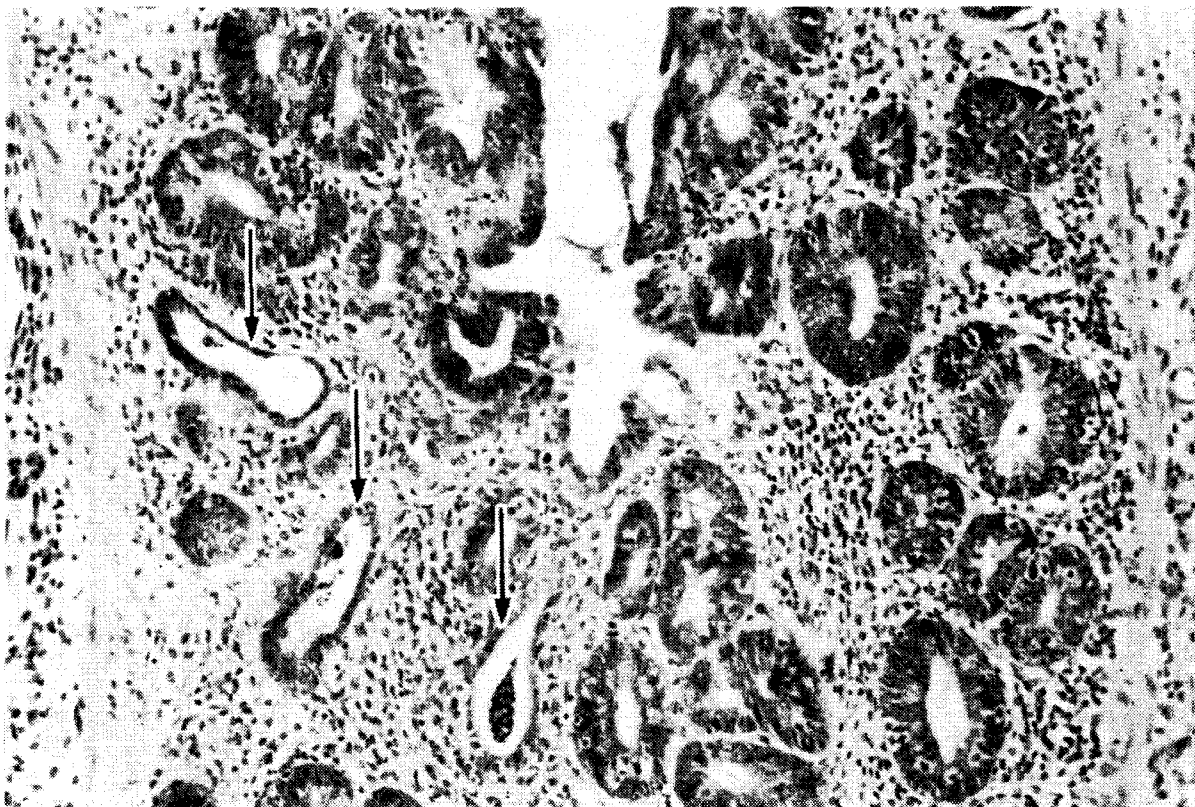


PLATE IV: 38. Chronic colitis in rat \rightarrow mouse chimaera 9 months after transplantation. Several cystically dilated degenerating crypts are seen (arrows), lined with flattened atrophic epithelium. The crypt at the base is filled with polynuclear leukocytes (crypt abscess). The other crypts are hyperplastic. (HE). Magnification $\times 120$

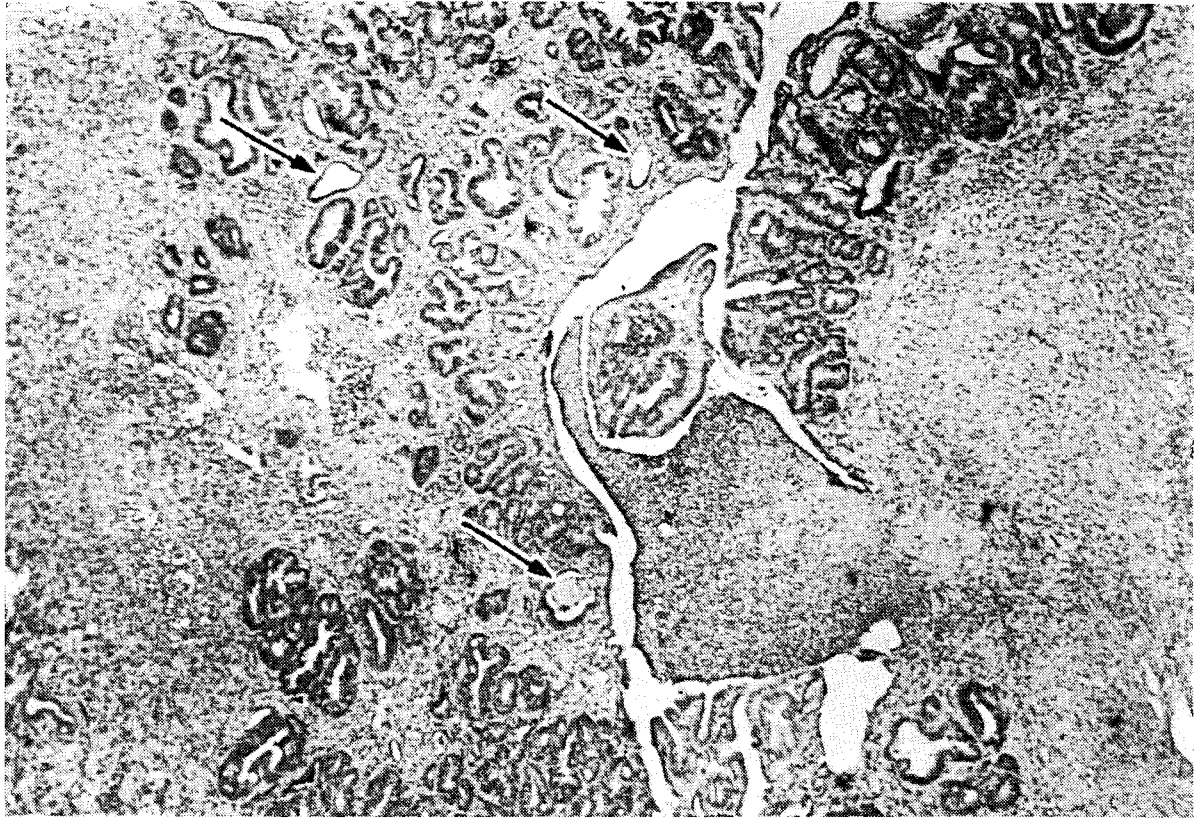

PLATE IV: 39(a). Chronic ulcerative colitis in rat → mouse chimaera at 6 weeks. A dense chronic inflammatory infiltrate spreads through all the layers of the colonic wall. Small funnel-shaped ulceration of mucosa at right. Several cystically dilated crypts showing a cystic change can be seen (arrows). (HE). Magnification × 30

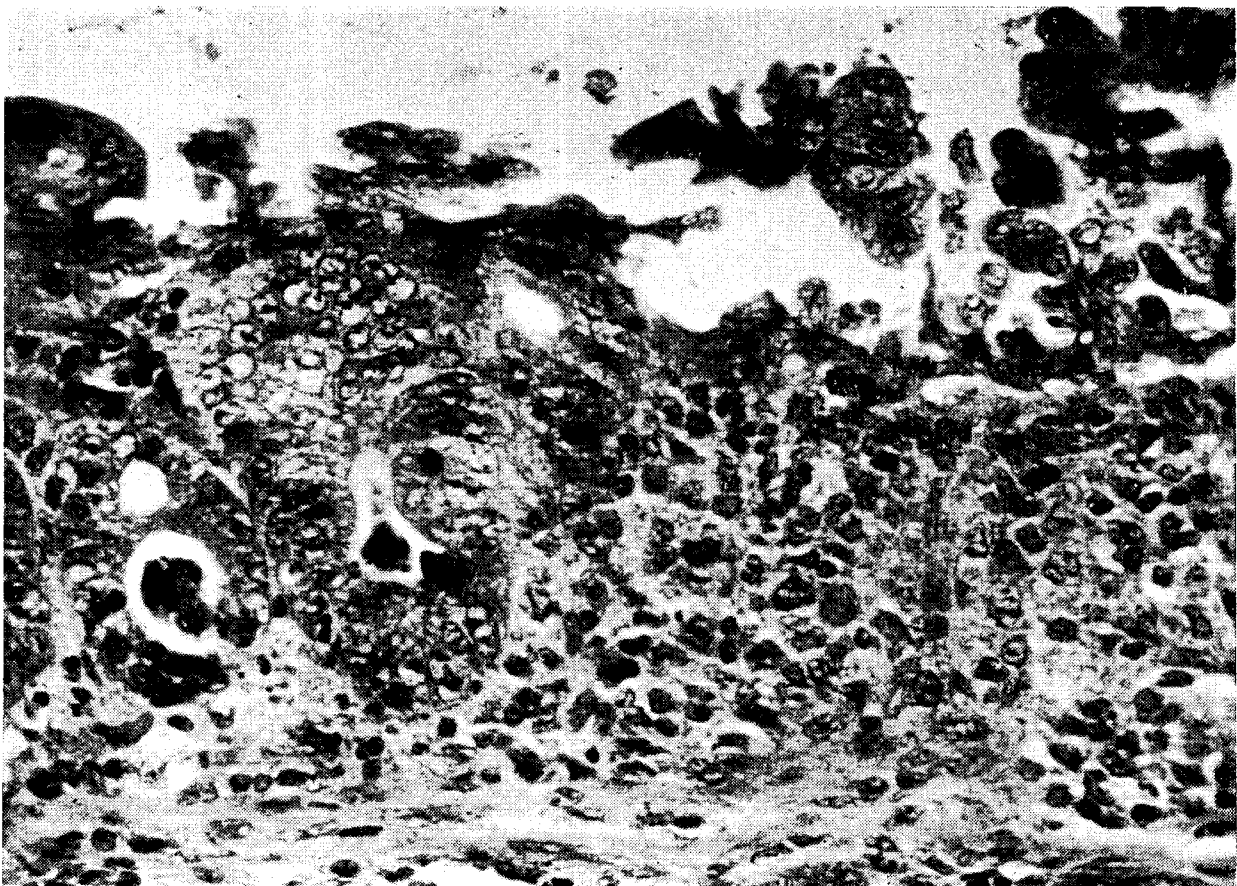


PLATE IV: 39(b). Crypt degeneration in colon of germ-free ND₂ mouse on day 17 following irradiation and treatment with rat bone marrow. The donor bone marrow was proved to be sterile. Note slight lymphoid cell infiltration; the mucosa at right side of picture is completely deprived of crypts. The lesion

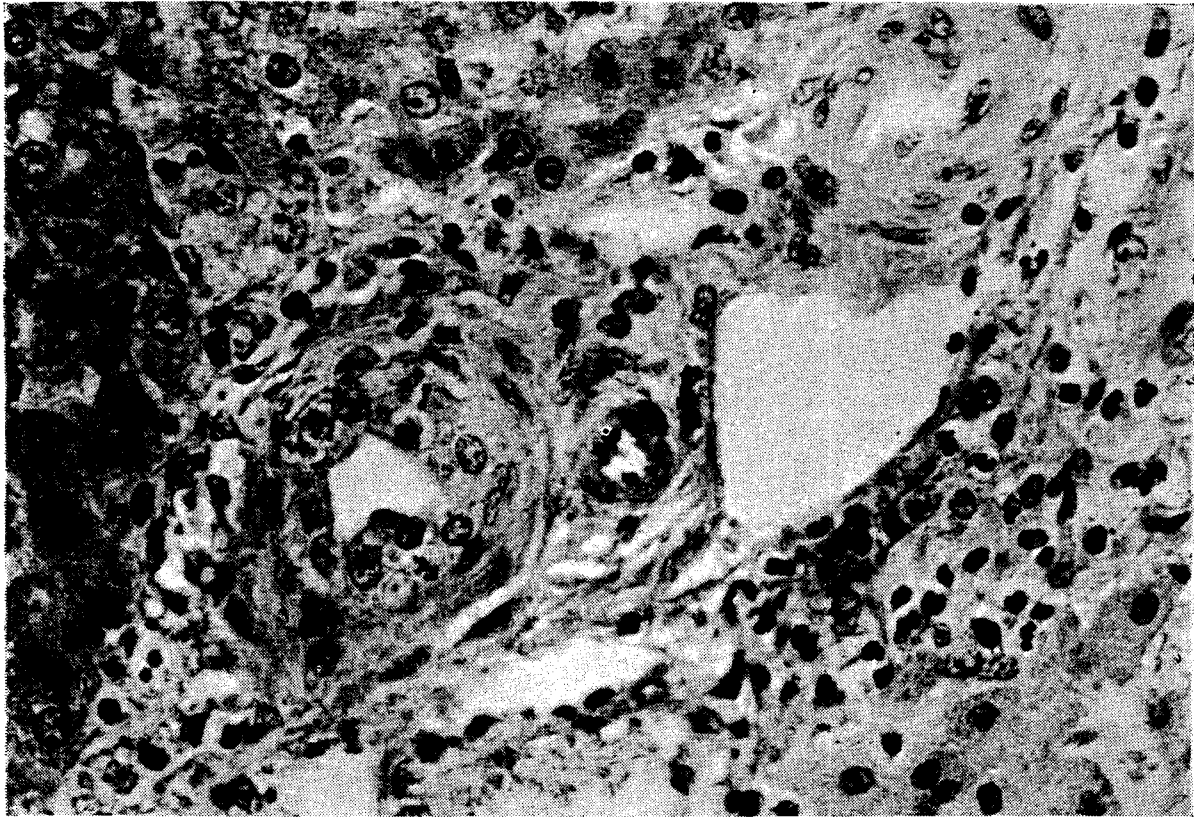


PLATE IV: 40. Degenerative changes in epithelium of small bile duct in homologous monkey chimaera on day 7. The epithelium is swollen and there is karyorrhexis of nuclei. Note slight infiltration of periportal space with lymphoid cells and histiocytes. (HE). Magnification $\times 300$

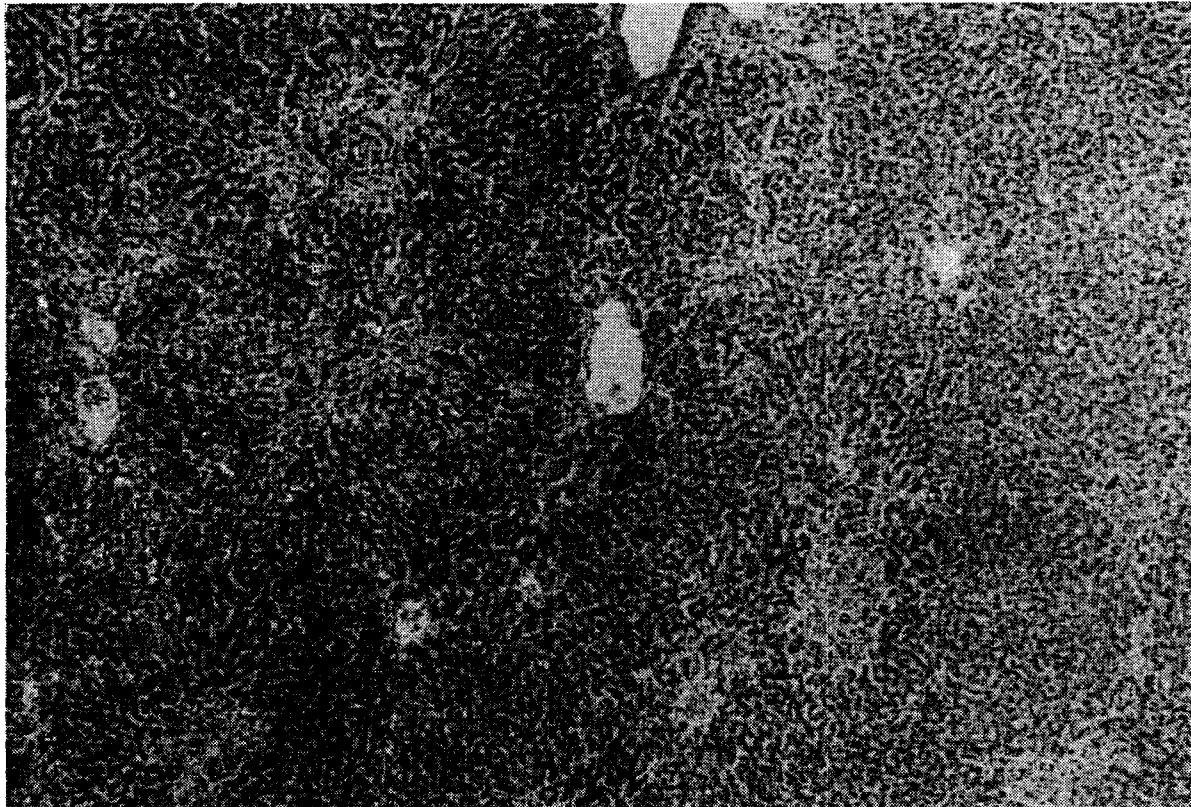

PLATE IV: 41. Multiple periportal foci of liver necrosis in 14-day old homologous monkey chimaera at day 14. (HE). Magnification $\times 30$

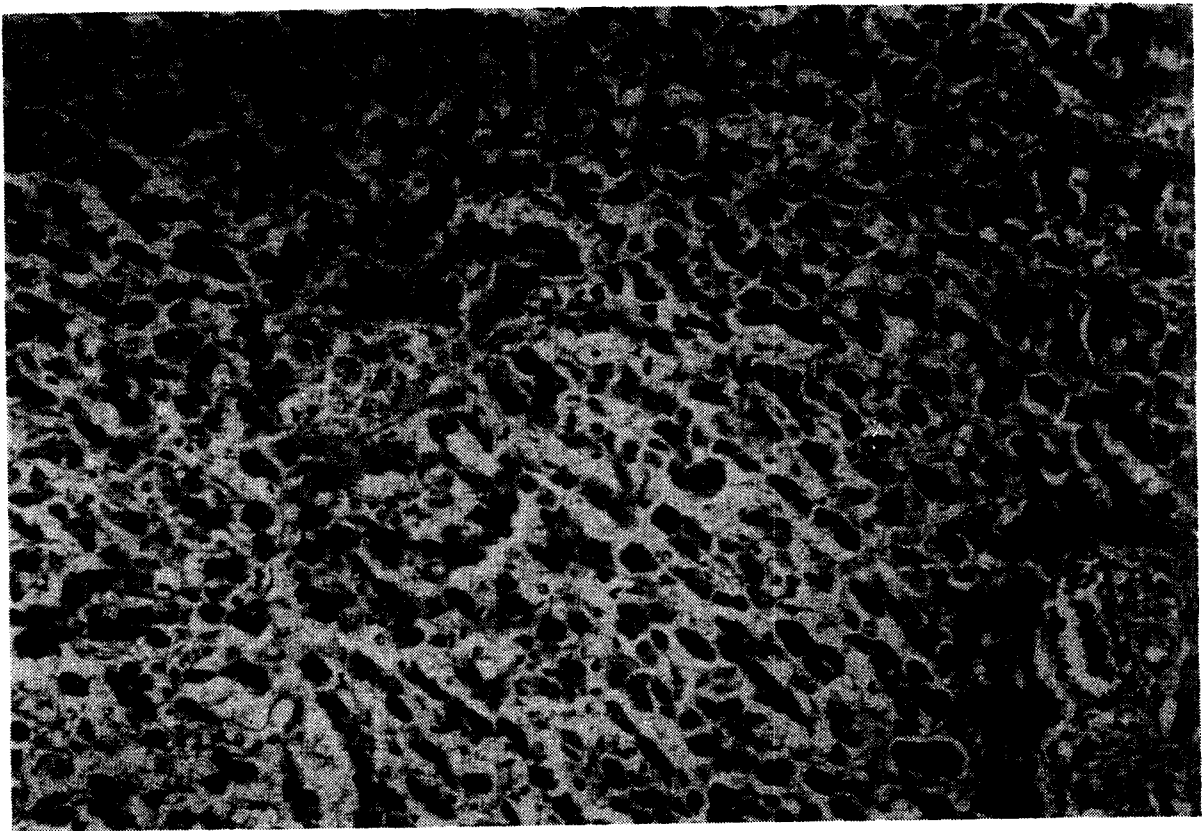


PLATE IV: 42. Massive dissociation and necrosis of liver parenchyma in homologous monkey chimaera at day 26. (HE). Magnification $\times 12$

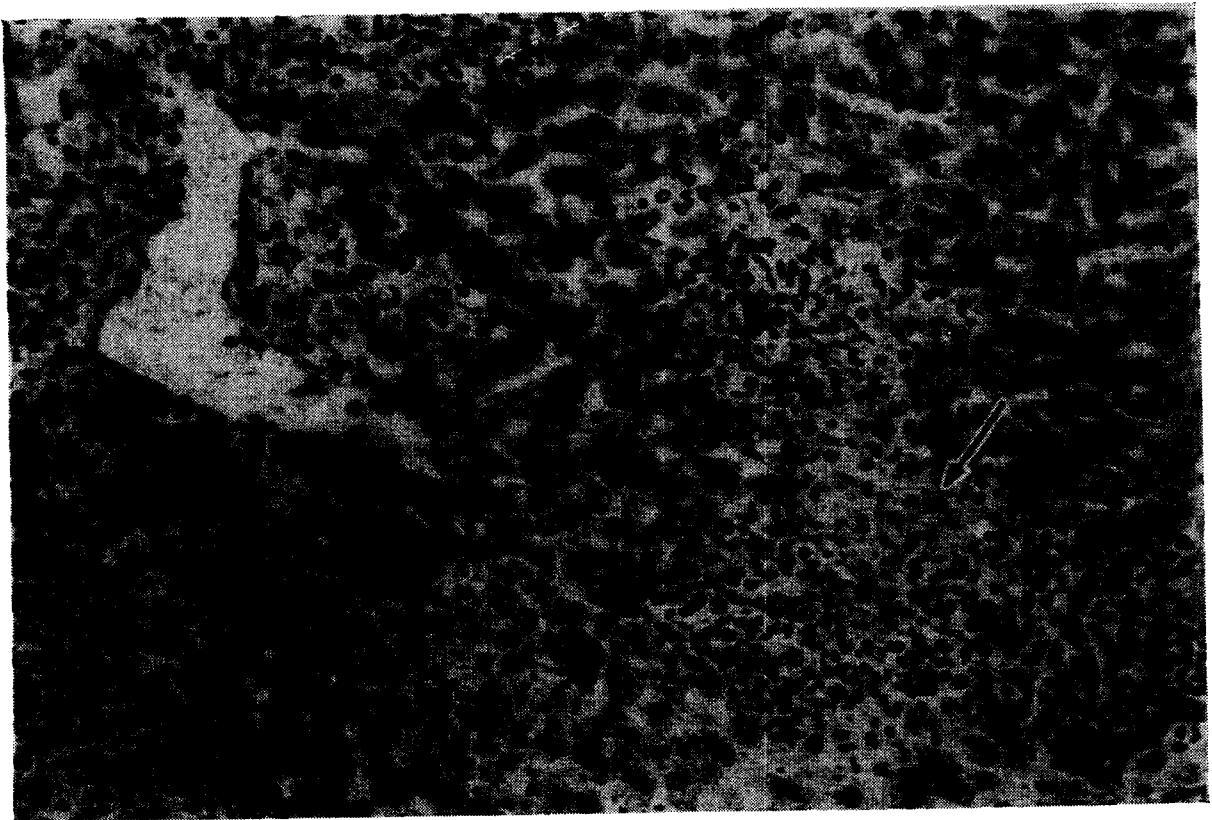

PLATE IV: 43. Pronounced histiocytic reaction in liver of homologous mouse chimaera (52 days). Histiocytes (epithelioid cells) have proliferated between liver cell cords. In upper left corner an infiltrate is protruding into the lumen of a vein. A focal necrosis is also present (arrow). (HE). Magnification $\times 190$

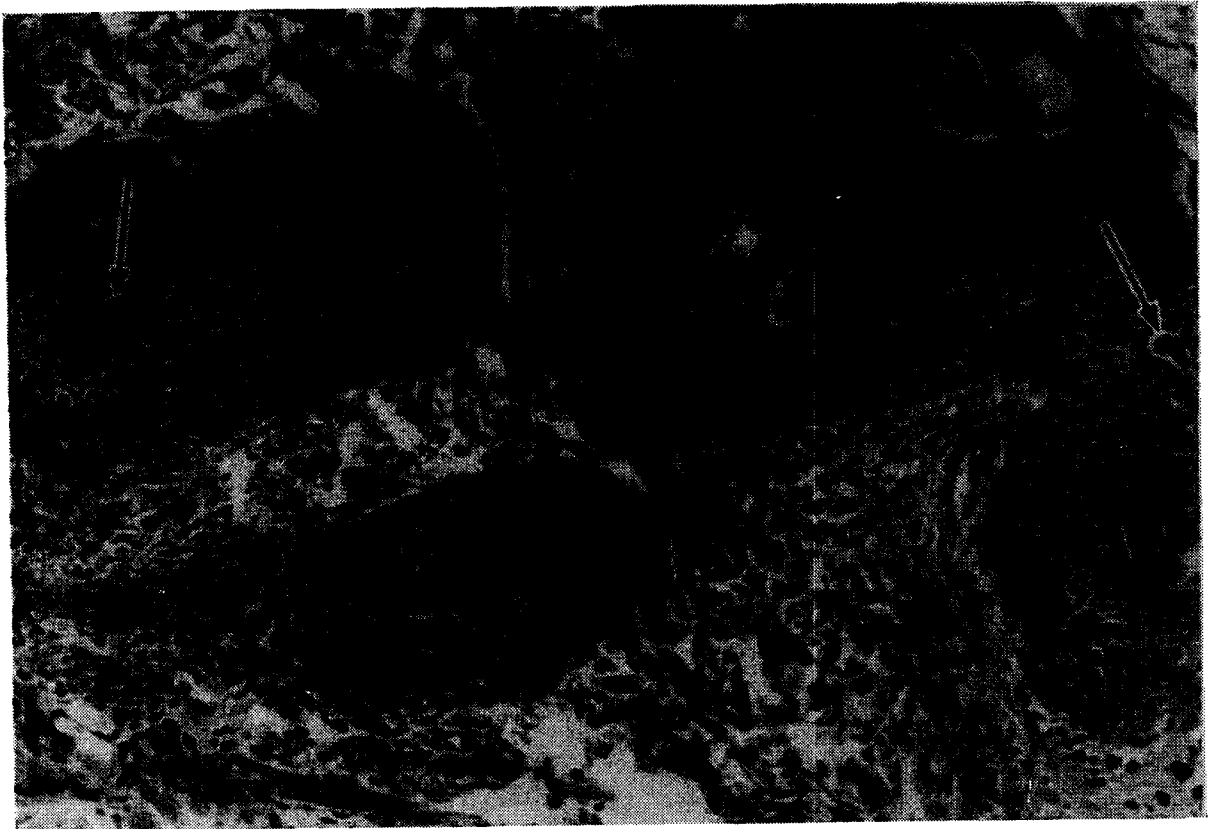


PLATE IV: 44. Severe acanthosis, follicular hyperkeratosis and dyskeratosis (2 dyskeratotic cells are indicated by arrows) in homologous monkey chimaera (26 days). Note dermal infiltrate of lymphoid cells and histiocytes, surrounding the hair follicles, extending into the epithelium. Compare with normal monkey epidermis in Plate IV: 45. (HE). Magnification $\times 120$

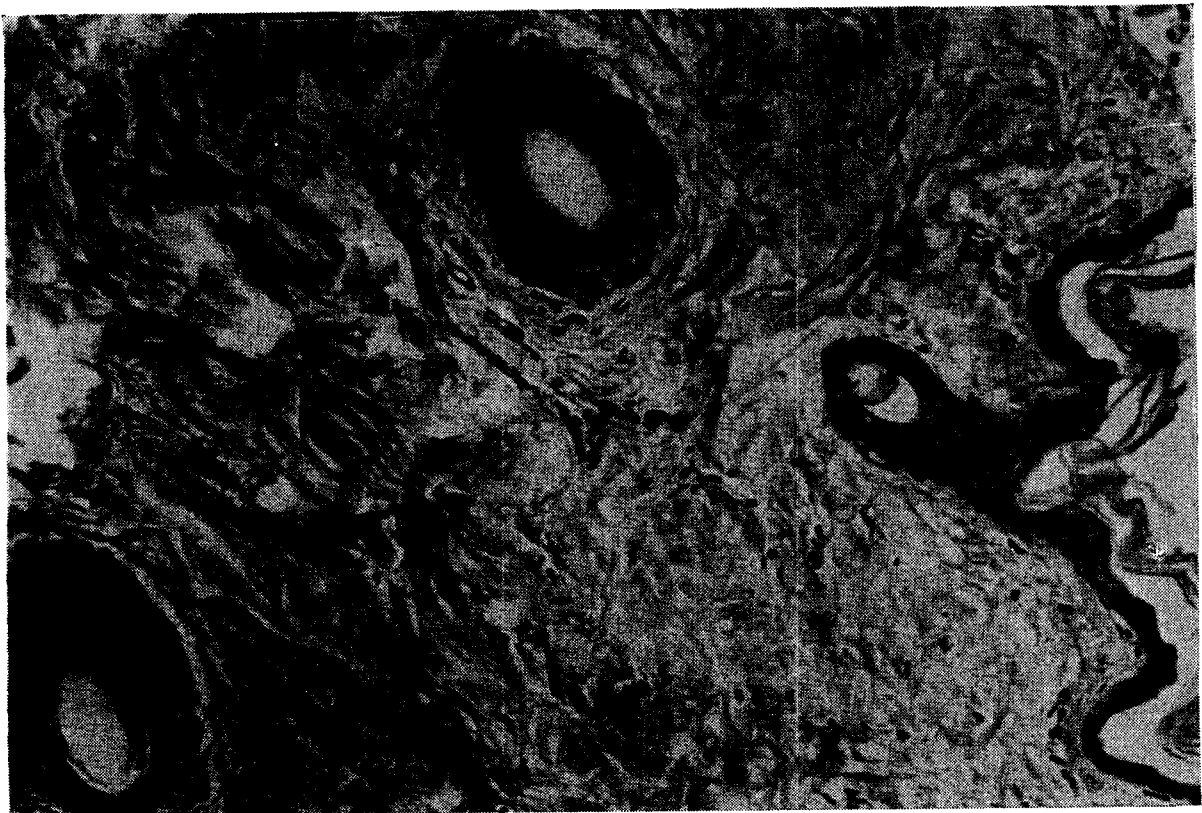

PLATE IV: 45. Skin of monkey irradiated 50 days previously and treated with autologous bone marrow. Completely normal appearance of the skin. Note that the epidermis has only 2-3 cells layers. (HE). Magnification $\times 120$

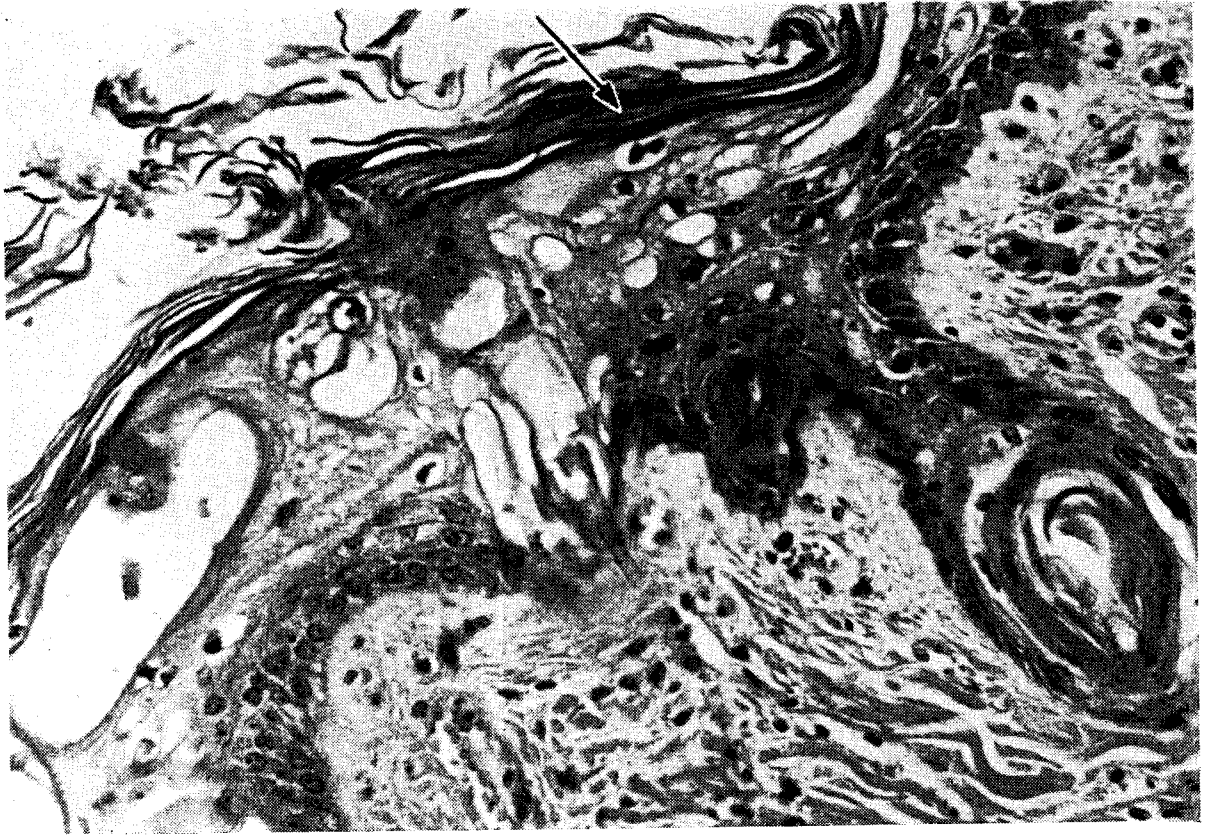


PLATE IV: 46. Vacuolar alteration of malpighian layer of epidermis, hyperkeratosis and parakeratosis (arrow) in homologous monkey chimaera (19 days). An atrophic hair follicle plugged with keratin is present. (HE). Magnification $\times 190$

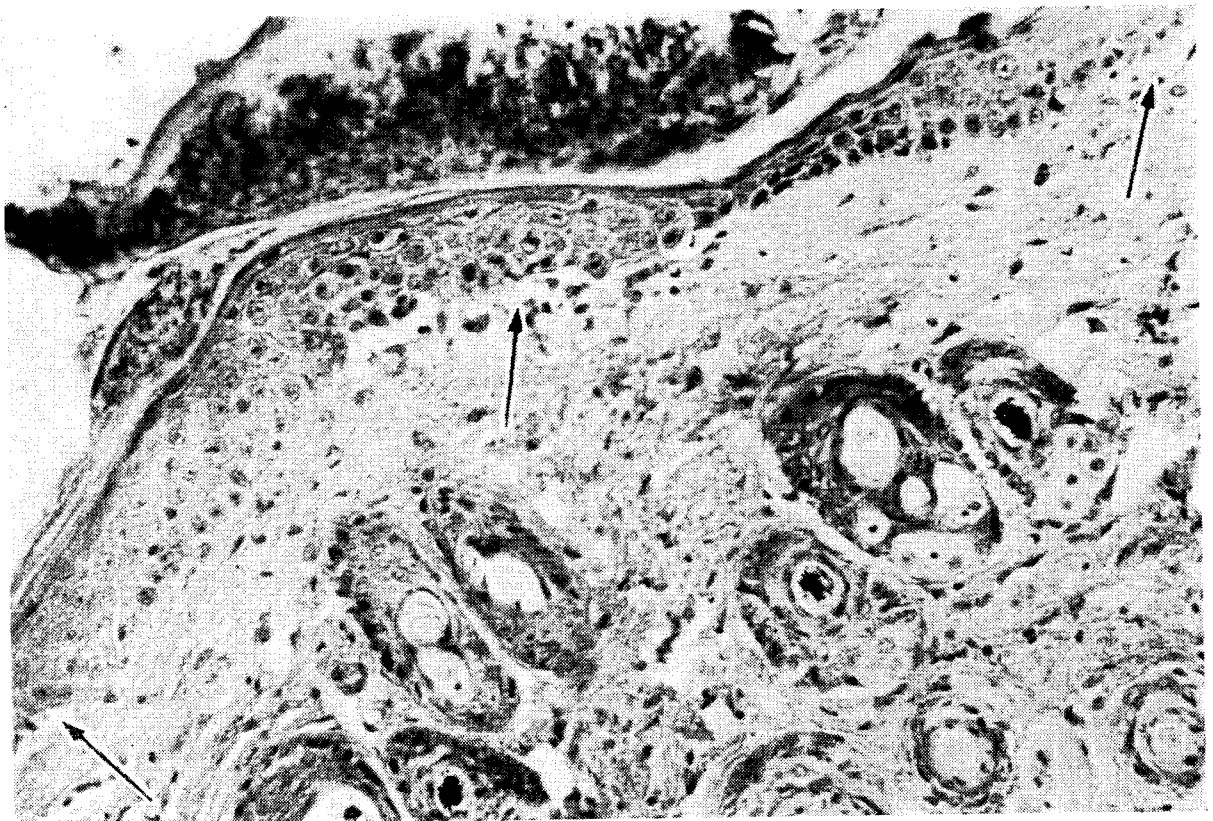

PLATE IV: 47. Basal cell vacuolisation (arrows) of epidermis in a homologous mouse chimaera at 2 months. In addition acanthosis and focal parakeratosis is shown. (HE). Magnification $\times 190$




PLATE IV: 48. Erythematous desquamative dermatosis in lethally irradiated leukaemic girl 12 days after homologous bone marrow transplantation (23 days after irradiation). Note also extensive scaling of the skin of the face of the patient in Plate III: 8. Photograph from Mathé *et al.* (1960)²⁶³

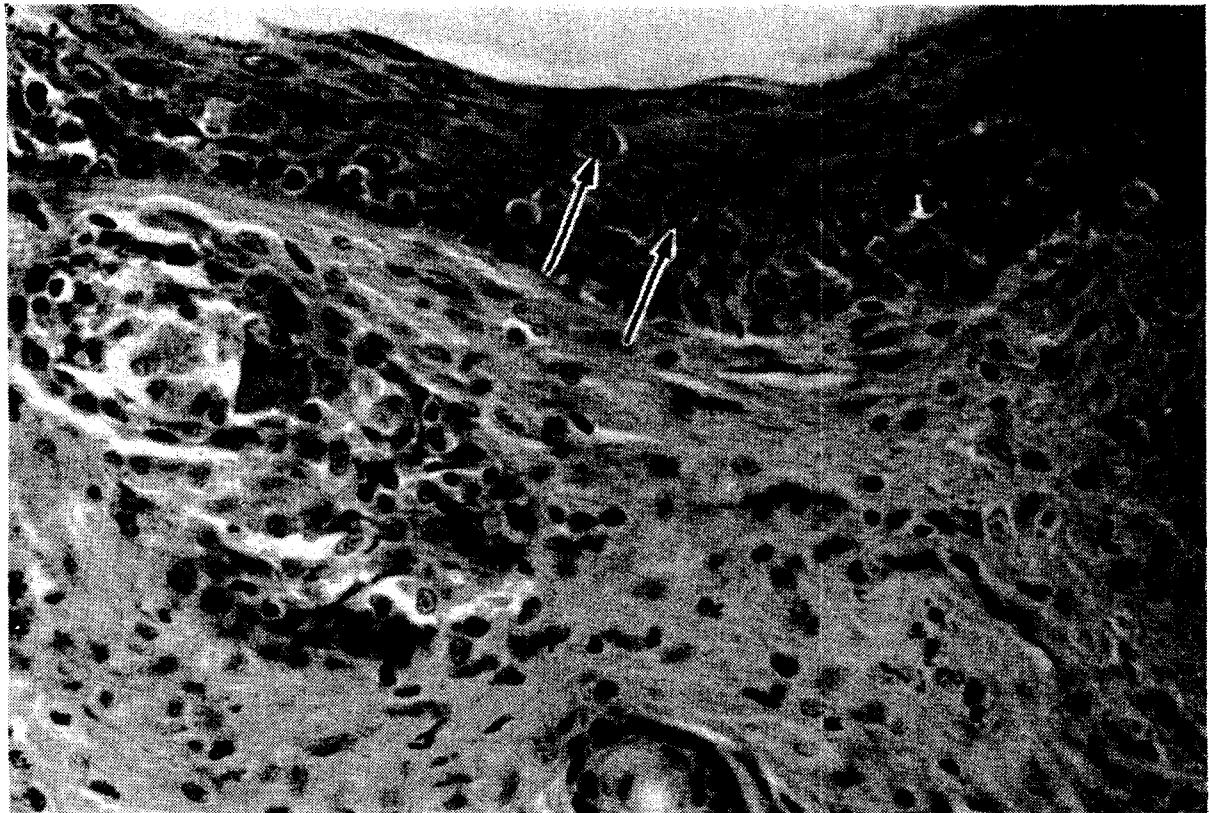


PLATE IV: 49. Acanthosis and dyskeratosis (arrows) of epidermis in mouse chimaera treated with rat bone marrow (5 weeks). Note lymphoid cells invading epidermis and partly destroyed hair follicle at left side. (HE). Magnification $\times 190$

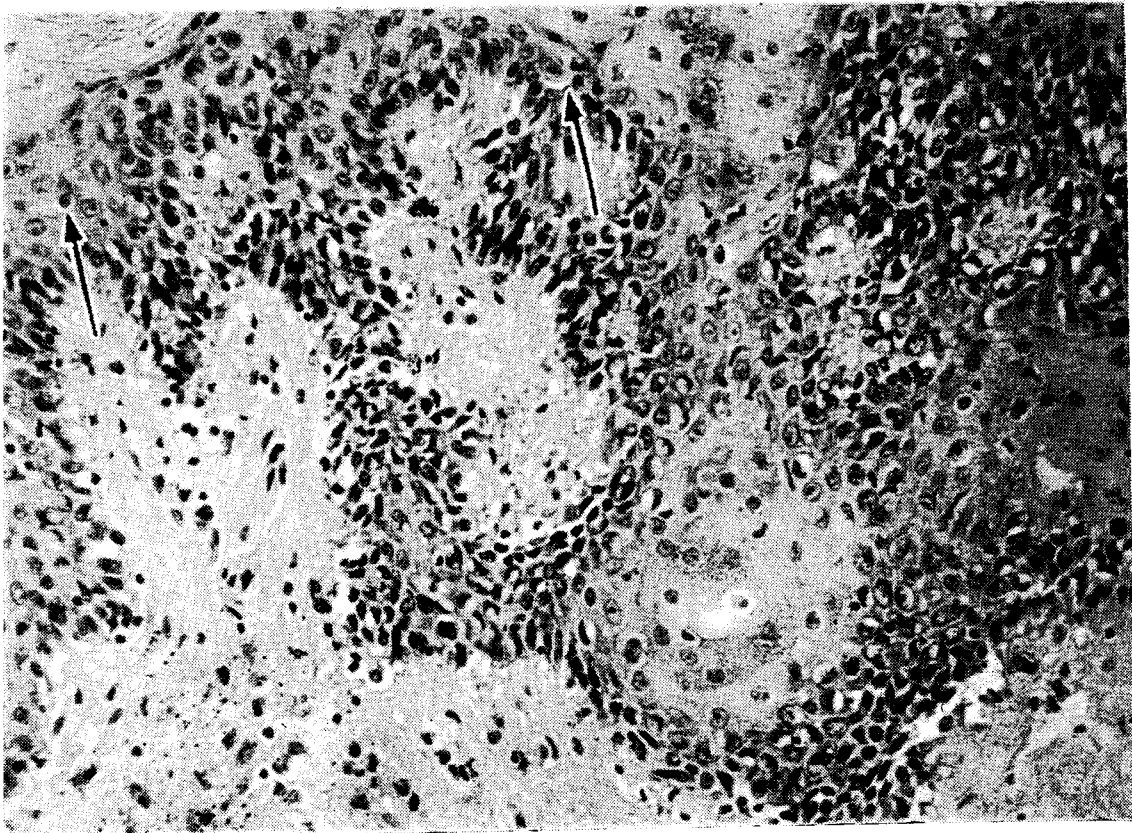


PLATE IV: 50. Infiltration by lymphoid cells accompanied by basal cell proliferation and hyperkeratosis of epidermis in lethally irradiated leukaemic child treated with autologous bone marrow. The child died 30 days later with severe secondary disease. Arrows indicate dyskeratotic cells. (HE). Magnification $\times 190$

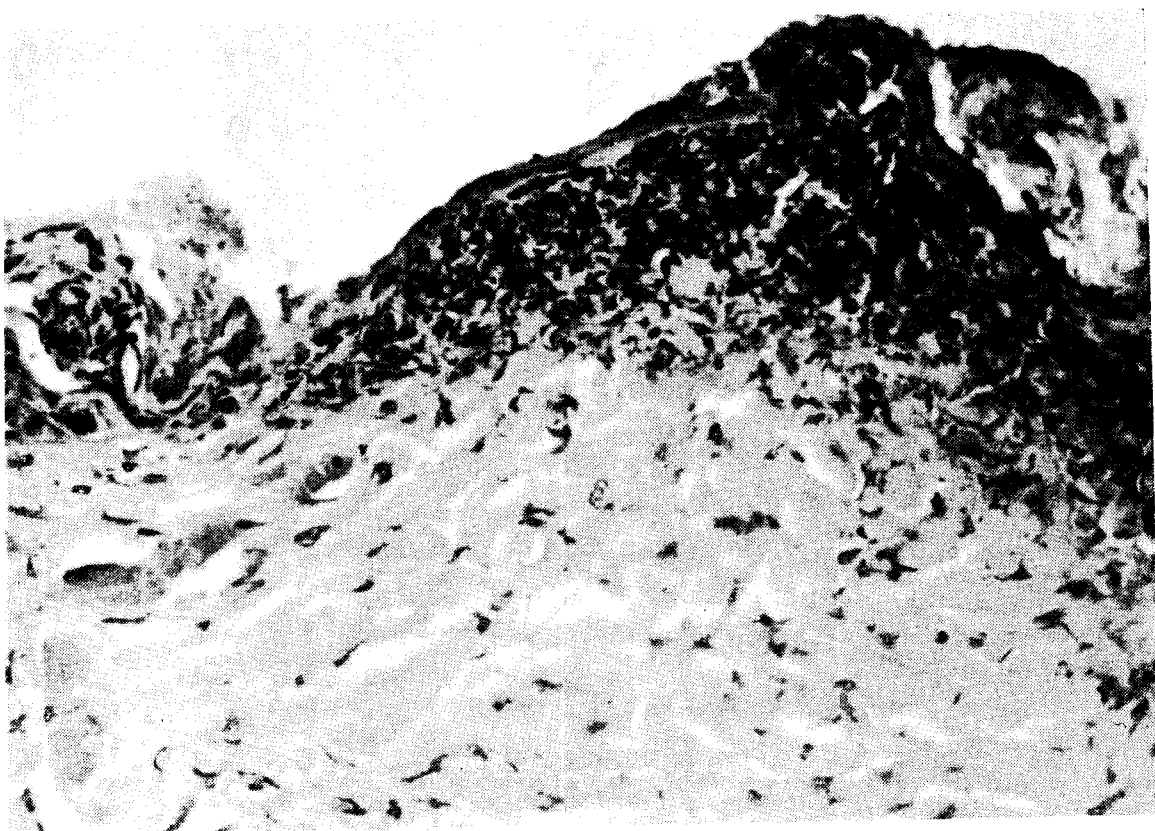


PLATE IV: 51. Total necrosis of epidermis in rat chimaera treated with bone marrow and spleen cells. Photograph from Balner (1963)¹⁴. (HE). Magnification $\times 300$

marrow transplantation and afterwards subsided. Similar changes although to a lesser extent occurred in a proportion of irradiated non-treated mice. It was concluded, therefore, that in these cases the reaction was due to bacterial antigens.

The splenic white pulp reaction is first evident between 24 and 48 hours after the irradiation and transplantation of foreign haemopoietic tissue when an enlargement of the splenic follicles is seen. This enlargement is due to an accumulation of large pale cells with vesicular pleomorphic nuclei possessing prominent nucleoli. The eosinophilic cytoplasm of these cells may or may not have a peripheral basophilic rim. In Giemsa-stained smears, reticular cells, histiocytes and plasmoblasts with irregularly shaped, lobulated or segmented nuclei and a few binucleated cells were noted. Among these cells mitoses are seen, a number of which show mitotic aberrations such as anaphase bridges, clumping of chromosomes, pyknosis and karyorrhexis at telophase.

Changes similarly indicative of the immunological reactivity of the host have also been observed in the cortex of the lymph nodes. From the 2nd day to the 6th day histiocytes, plasmoblasts and plasma cells appear in the red pulp of the spleen and the medullary cords of the lymph nodes. In smears these cells show nuclear abnormalities as described above.

Three arguments may be put forward in support of the view that the splenic white pulp reaction is a response on the part of the host and represents, therefore, a relatively radioresistant part of the host's immunological reactivity. Firstly, appearance of the cells taking part in the reaction precedes the proliferation of bone marrow cells in animals treated with bone marrow and that of lymphoblasts and lymphocytes in animals treated with lymph node or spleen suspensions. The reactive cells seem to disappear when proliferation of the grafted cells is evident histologically (4th day). Secondly, a similar reaction may occur in irradiated non-treated animals stimulated with non-cellular antigens. Thirdly, nuclear and mitotic aberrations suggest that these cells have been damaged by radiation. Furthermore, the reaction is even more prominent and persists till the 6th and 7th day in sublethally irradiated animals.

It may be assumed that the histiocytes, plasmoblasts and plasma cells which appear after the 2nd day are partially abnormal descendants of the relatively radioresistant immunologically reactive reticular cells. It might well be that these are the cells which are involved in an

immunological reaction of the host against the graft which, in a proportion of cases, might result in graft rejection.

On the other hand, it is clear that this residual host reactivity can only persist temporarily and will decline rapidly. Since both the reticular cells and their descendants display morphological signs of radiation damage, it may be assumed that these cells have a restricted life span or, alternatively, that delayed radiation induced death will occur after one or more divisions. The splenic white pulp reaction subsides accordingly, after the 3rd day and this may well be related to the fact that graft rejection occurs in a variable proportion of animals following the minimum LD₁₀₀ dose of radiation and only rarely after higher doses.

THE PATHOLOGY OF GRAFT REJECTION

In the animals in which the graft is rejected, persistent pancytopenia or development of reticulocytopenia, aplastic anaemia, neutropenia and thrombocytopenia occurs after initial recovery in the first month following lethal irradiation doses. The bone marrow in such animals shows arrest of maturation, necrosis of haemopoietic tissue or various degrees of hypocellularity (Plate IV: 12). Interestingly, massive karyorrhexis is also seen in the lymphatic follicles of the lymph nodes and spleen, indicating that lymphoid cells derived from the donor are destroyed concurrently with the haemopoietic cells. The cell fragmentation in the lymph nodes is especially marked around small blood vessels and lymphatic channels. In the red pulp of the spleen, at the site of extramedullary haemopoiesis, massive deposition of fibrinoid substance is a notable feature (Plate IV: 13).

A peculiar granulomatous reaction has been observed in the destroyed haemopoietic and lymphatic tissues of animals which reject their graft. Massive proliferation of reticuloendothelial cells of an epitheloid type occurs in the red pulp of the spleen, the lymph nodes and the bone marrow⁹⁴. In addition, multinucleated cells of the foreign-body type are seen. It is not known whether the epitheloid cell reaction is primarily connected with the antibody-response against the graft, or whether it represents an aspecific histiocytic response to cellular disintegration. Following sublethal radiation doses the described changes occur between 6 and 8 days after the irradiation and grafting of foreign marrow.

The animals that reject their graft die with the usual changes of

the bone marrow syndrome which have been described previously, viz. septicaemia, haemorrhage and severe anaemia.

Secondary disease

In contrast to the graft rejection discussed in the previous paragraph an immunological reaction of the graft against the host is usually a far more important cause of delayed mortality in lethally irradiated homologous or heterologous radiation chimaeras. The animals show a complex of symptoms which is now preferably denoted as secondary disease. In broad outline the pathological changes characteristic of secondary disease have many similarities in common in a variety of animal species: mice, rabbits, rats, dogs, monkeys and man (see Table III: 4).

A number of factors may influence, however, the incidence, the extent and the type of the various lesions, e.g. the species of donor and recipient, the radiation dose, the number of lymphoid cells contained in the injected cell suspensions, the previous sensitisation of the host by donor antigens and the duration of the chimaeric state.

In particular, the occurrence of extensive early proliferation of donor lymphoid cells in the host may determine the prevalence of either the lesions found in the early form of secondary disease (degenerative changes in the intestines, the liver and the skin) or the lesions found in the more chronic forms of secondary disease (inflammatory changes due to infectious processes).

General pathology and pathogenesis of secondary disease

Secondary disease may be defined as a disease of radiation chimaeras which causes morbidity and mortality in the presence of a regenerating bone marrow graft and in which the characteristic lesions of the bone marrow syndrome are absent.

The fundamental change in secondary disease is infiltration with lymphoid cells and histiocytes associated with the degeneration and loss of cells in a great variety of organs other than the bone marrow. These changes may take the form of isolated cellular degeneration and in that case they are found only on detailed histological inspection (Plate IV: 14). Enlarged cells may be found disseminated throughout the tissues which show increased eosinophilia of the cytoplasm and nuclear pyknosis. In addition, an increased mitotic frequency is noted, which suggests a compensation for the loss of cells.

In a number of tissues more extensive damage is inflicted as is

revealed by necrosis and degenerative changes (pyknosis, karyorrhexis and fragmentation) of large numbers of cells. In addition to cellular degeneration, regenerative changes are apparent to a varying extent in most of the affected tissues, which suggests that the capacity for cell division is not primarily impaired.

The combination of degeneration and repair gives the lesions a rather complex appearance. In some tissues, e.g. the intestinal epithelium, the degenerative changes prevail, which results ultimately in mucosal denudation. In other organs, e.g. the epidermis, cell death as evidenced by dyskeratosis and vacuolar degeneration, is often of minor importance compared with the massive regeneration. The latter may lead to hyperplastic changes such as acanthosis (Plate IV: 15), which is partly responsible for the characteristic appearance of the skin in secondary disease. Rats, when treated with lymphoid cells in addition to bone marrow, are an exception in this respect, since extensive necrosis of the epidermis may occur in this species. In the surviving animals these lesions may eventually heal. In general, the recovery of the affected tissues may be either complete or fibrosis and atrophy may develop at the site of lesions inflicted earlier.

One other aspect of the primary lesions which appear in secondary disease seems to be particularly important in connection with the pathogenesis of the syndrome. In most tissues and especially in those which are severely affected—intestinal mucosa, skin and liver—slight to heavy infiltration with round cells, probably lymphoid cells and histiocytes, is characteristic. Lymphocytes appear to have penetrated into the epithelium of the hair follicles, the epidermis, the intestinal crypts and the periportal connective tissue of the liver. One often finds degenerating epithelial cells in the immediate vicinity of the invading cells (Plate IV: 16). It seems logical, therefore, to connect the round cell infiltration with the presence of dead cells. Evidence has been accumulated that the lymphoid cell population in the lymphatic tissues of the host is predominantly if not completely of the donor type. It is attractive to postulate, therefore, that immunologically competent cells migrate from these tissues to peripheral sites and that a cytotoxic effect on host cells in a number of target tissues is a direct consequence of the immunological activity of the donor cells.

Specific pathology

LYMPHATIC TISSUES

The changes in the lymphatic tissues are partly dependent on host species, host-donor combinations, radiation dose and the number of lymphoid cells injected.

As has been mentioned earlier, in some homologous and parent to F_1 combinations in mice, treatment with bone marrow only is followed by complete repopulation of the lymphatic tissues with lymphoid cells. Compared with isologous combinations in the same species, the recovery occurs at the same rate or is only slightly retarded⁴⁴². Significantly, in these combinations, no symptoms, or only minor ones, of secondary disease are apparent.

In other homologous combinations and after treatment with rat bone marrow, regeneration occurs initially, as revealed by a few mitoses and the appearance of blast-cells and small collections of mature lymphoid cells, at the end of the first and in the course of the second week following treatment (Plate IV: 17). After the third week, when the animals suffer from severe secondary disease, it is common to find complete atrophy of the lymphatic tissues.

The splenic follicles of these mice are small and composed only of reticular cells (Plate IV: 18). The cortex of the lymph nodes is contracted, and a few lymphocytes are dispersed in an empty reticular stroma. The sinusoids are dilated and filled with histiocytes, which frequently contain phagocytosed erythrocytes or haemosiderin granules (Plate IV: 19). In the medullary cords varying numbers of plasma cells may be present. Similar atrophic changes are found in the thymic cortex. Frequently, deposition of collagen occurs in the lymphatic follicles of spleen and lymph nodes.

In mice surviving the period during which secondary disease is clinically observable, regeneration of the lymphatic tissues is eventually seen. After the second month complete restoration may be found in a varying proportion of animals (Plate IV: 20).

A similar atrophy of the lymphatic tissues, as was described for mice, has been observed in children who died following irradiation and treatment with homologous bone marrow. This characteristic biphasic response of the lymphatic tissues which occurs in incompatible host-donor combinations has been described most completely in lethally irradiated monkeys⁴⁴⁶ and rabbits³²⁵ treated with homologous bone marrow, and in irradiated F_1 hybrid mice treated with

parental lymph node cells in addition to bone marrow²⁵². Initial proliferation of lymphoid cells in the first two weeks is followed by widespread necrosis of the partially regenerated lymphatic tissues and subsequent atrophy. In the early regenerative phase many lymphatic stem cells, transitional cells, plasma cells and histiocytic cells are seen (Plate IV: 21). In the degenerative phase massive karyorrhexis and fragmentation of lymphoid cell occurs, while the reticular supporting stroma remains intact (Plates IV: 18, 22). Deposition of fibrinoid substance in the centre of the lymphatic follicles may be a characteristic finding.

As was mentioned in the previous chapter, Gorer and Boyse¹⁶² as well as Congdon and Urso⁹⁹ have related the destruction of lymphoid cells to an antigen-antibody reaction and have pointed to the similarity of this phenomenon with that observed in certain "allergic" reactions. When the lymphoid cells come into contact with host antigens, both the antibody-producing and antigen-carrying cells are destroyed in the reaction (so-called "allergic death" of cells) and the continuation of this mutually destructive process leads to exhaustion atrophy of the lymphatic tissues. Thereafter, the severity of the primary effects of the graft anti-host reaction diminishes, but secondary effects of the atrophy of the lymphatic tissues may cause other complications which will be discussed in the following section.

It might be thought that the atrophy of the lymphatic tissues is due to the debilitated condition of the animals. Generalised and complete destruction of the lymphatic tissues is, however, a rare phenomenon and only seen in very acute infections or as a transient feature after massive doses of cortisone. We may accept, therefore, that changes in the lymphatic tissue are a consequence of an immunological reaction as described above and are specific for graft versus host reactions in general and secondary disease in particular.

In homologous rabbit³²⁵ and mouse chimaeras^{99, 445} a striking granulomatous reaction has been described in lymph nodes and spleen, which is probably related to the destruction of lymphoid cells in the regressive phase following early regeneration. Many histiocytic cells of epitheloid morphology appear in addition to multinucleated cells of the foreign body type (Plate IV: 23). As discussed earlier, a similar granulomatous reaction has been found in the haemopoietic tissues during a graft rejection, i.e. as a consequence of a host versus graft reaction (see page 136). It is not known whether the histiocytic cells are immunologically active and involved in an immunological

reaction, either graft versus host or host versus graft, or whether the histiocytic response represents merely a secondary reaction to cellular degradation products.

It should be stressed at this point, that deposition of fibrinoid substance and plasma cell infiltration are both features which *cannot* be considered as specific for secondary disease or any other reaction to tissue antigens, since both are regularly seen in irradiated animals not treated with haemopoietic cells.

In lethally irradiated mice treated with large numbers of foreign lymphoid cells (1×10^6 cells and more) an apparently excessive regeneration occurs in the lymphatic tissues. The animals presumably die at an early stage before the secondary atrophy occurs. The histological manifestations of this acute killing effect are as follows: On the 4th day collections of large cells with pale nuclei and a varying amount of cytoplasmic basophilia appear in the centre of the splenic follicles and the cortex of the lymph nodes (Plate IV: 24). In smears these cells can be identified as lymphoblasts and young lymphocytes. Many mitoses are seen which usually show no aberrations. This suggests that these cells have not been irradiated and are, therefore, of donor origin. In the following 2 days the accumulations of immature lymphoid cells greatly enlarge, the entire lymphatic tissues being massively infiltrated and showing a resemblance to lymphosarcoma. In addition to lymphoblasts and lymphocytes many plasmoblasts and plasma cells are present. It seems likely that the enormous proliferation of what are presumably donor type lymphoid cells is responsible for the early mortality and the severe character of the disease in these animals. The lymphoid cells produced in these tissues may migrate to peripheral sites and inflict widespread cytotoxic damage, especially to epithelial cells.

As has been discussed in Chapter III, specific, complete or partial immunological tolerance of the graft towards the host may develop in a chimaera after a variable time, depending on the host-donor combination. In homologous or heterologous mouse chimaeras suffering from secondary disease, the development of tolerance seems to coincide with a diminishing severity or disappearance of symptoms of secondary disease and a recovery of the animal's immune reactivity against infective agents.

Histological examination of the lymphatic tissues of such mice has shown that following atrophy of the lymphatic tissue present during the period of secondary disease, gradual repopulation with lymphoid

cella parallels the development of tolerance. It seems very likely that this new population of donor lymphoid cells which has been demonstrated to be partly or completely non-reactive towards host antigens, reacts normally against both other tissue antigens and also bacterial and viral antigens. This would explain the improvement of the clinical condition of these animals. The diminished anti-host reactivity can, by itself, explain the termination of the period of continuous lymphoid cell depletion, because overwhelming "allergic death" of lymphoid cells caused by an excess of host antigens no longer occurs.

The relationships outlined above between the cellularity of the lymphatic tissues and the age, clinical condition and immunological reactivity of the radiation chimaera are schematically represented in Fig. IV¹.

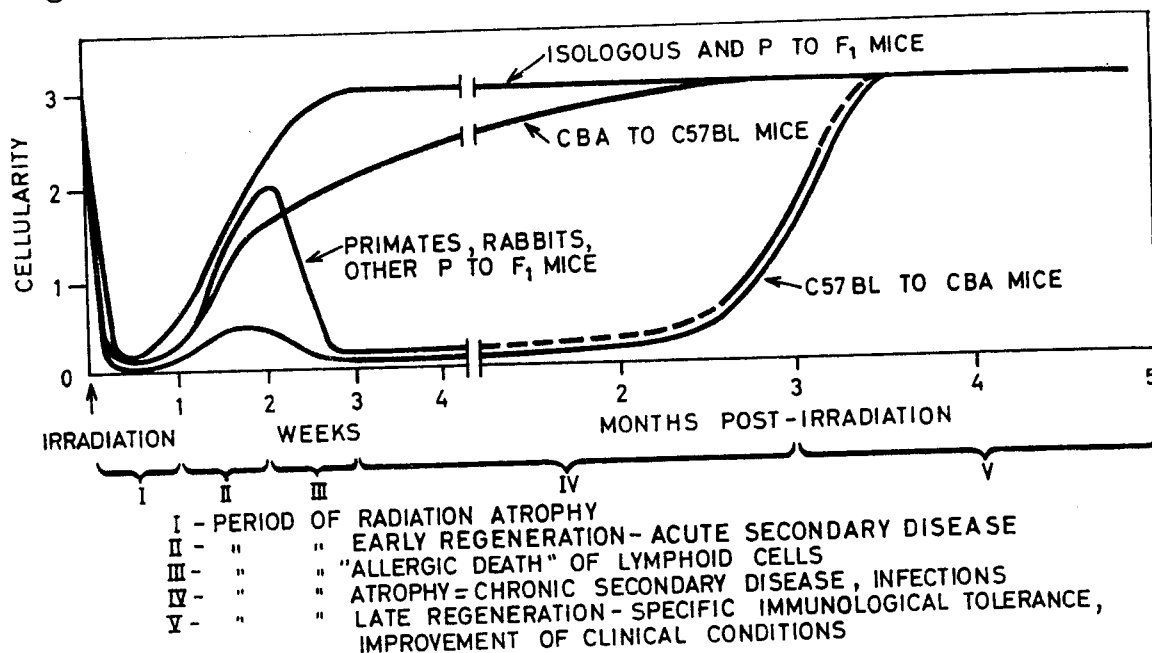


Figure IV¹. Cellularity of lymphatic tissues, clinical condition and immunological reactivity of chimaeras. The cellularity of the lymphatic tissues has been arbitrarily estimated by recording the presence of follicles, lymphoblasts, mitotic activity and the number of mature lymphocytes.

- o = total atrophy
- 1 = a few lymphoblasts, mitoses
- 2 = advanced regeneration, mature lymphocytes present, follicles of subnormal size and in subnormal numbers
- 3 = normal appearance

INFECTIOUS DISEASE

As has been discussed in the preceding section, severe atrophy of the lymphatic tissues may occur in chimaeras (mainly bone marrow

treated mice) surviving the first 2 weeks following treatment. This atrophy may explain the impairment of immunological defence against infective agents, which expresses itself as an increased susceptibility of these chimaeras to infections.

Other factors probably promoting infection are radiation induced lesions creating a *porte d'entrée* and lesions caused by the primary effects of the graft versus host reaction. Without a doubt the latter factors are of importance in the causation of the inflammatory lesions frequently found in the intestines of mouse chimaeras.

Among the most important infectious lesions found in mice, rabbits, dogs, and monkeys suffering from secondary disease are bacterial bronchitis and pneumonia. In some mouse experiments the incidence of pneumonia has been so high as to become the major cause of death. Miscellaneous lesions found in mice which are presumably caused by bacterial invasion are endocarditis, abscesses of the salivary glands and epididymitis. In dogs interstitial nephritis due to *Leptospira canicola* has been described. In monkeys pericarditis and cystitis was observed in a few cases.

Evidence has been accumulated that radiation chimaeras may be exceptionally sensitive to virus infections or, alternatively, widely prevalent latent viruses may become activated in the immunologically crippled animals. In a large proportion of dogs that died after treatment with homologous bone marrow, focal necrosis of the liver was found, evidence suggestive of contagious canine hepatitis⁴⁰⁰. In several of these cases, inclusion bodies characteristic of this disease were found in cells of the liver and other organs. In other dogs lesions suggestive of distemper occurred: liver necrosis, bronchitis, bronchiolitis, interstitial pneumonia, with metaplasia of the bronchial epithelium and epithelialisation of alveoli, and inclusion bodies in the epithelial cells of the urinary tract.

In monkey chimaeras several cases suspected of virus infection have been reported.⁴⁴⁶ In one case interstitial pneumonitis was found with foci of desquamation of alveolar cells and acidophilic nuclear inclusion bodies in cells lining the alveoli and the terminal bronchioles (Plate IV: 25). Another case showed ulcerative colitis. In the mucous membrane many large cells were present with amphophilic nuclear inclusion bodies surrounded by a clear halo (Plate IV: 26). The inclusion bodies resembled those found in herpes infection and cytomegalic inclusion disease (salivary gland virus disease). Focal collections of histiocytic cells with similar inclusions were found in the

spleen of a third monkey. Hepatitis showing a morphology suggestive of a viral aetiology with many nuclear inclusion bodies in liver cells has been observed only once in a monkey chimaera. Comparable lesions were never encountered in irradiated control monkeys, monkeys treated with autologous marrow or non-irradiated monkeys of the colony.

In a 6-year-old boy—one of the leukaemic children successfully transplanted with bone marrow by Mathé *et al.*—adrenal lesions reminiscent of viral infection were observed which resembled those found in the intestines and spleen of the monkeys described in the preceding section²⁶³. The adrenal cortex showed areas of focal necrosis at the margin of which giant cells with amphophilic nuclear inclusion bodies were seen (Plate IV: 27).

Infection with mycelia or yeast-like organisms may complicate secondary disease in several species. In a dog treated with homologous bone marrow *Candida* was found in ulcers in the ileum⁴⁰⁰. In monkeys dermatitis and necrotising oesophagitis with abundant growth of yeast-like organisms have been reported⁴⁴⁶. In one of these cases the organism was cultivated and identified as *Candida albicans*. Necrotising bronchitis with the presence of mycelia in the bronchial lumen occurred in one of Mathé's clinical cases, a child suffering from secondary disease following homologous bone marrow transplantation. In a second case massive mycelial septicaemia explained the presence of meningitis and areas of cerebral colliquative necrosis. In the meningeal membrane, the cerebral vessels and the brain substance numerous mycelial threads were shown to be present²⁶³.

Candida albicans is a widely distributed normally harmless inhabitant of the intestinal tract. It is presumed that invasiveness of this organism and ensuing systemic infection is promoted not only by the impairment of the immunological defence but also by the treatment with broad-spectrum antibiotics often used to prevent bacterial infection.

Finally, the list of infective agents which endanger the health of the radiation chimaera would not be complete without the mention of helminths. Rhesus monkeys are heavily infected with a nematode, *Oesophagostomum apiostrum*, a parasite allied to the human hookworm. The worm penetrates the colonic mucosa and may be buried deep in the intestinal wall. Secondary bacterial infection of the worm lesions is a major complication. Perforation and peritonitis have been cited as explanations for the death of a number of monkeys harbouring

this parasite, after irradiation and treatment with homologous bone marrow. It may thus be visualised that the intestinal worm lesions promote bacterial septicaemia in the immunologically crippled chimaera.

HAEMOPOIESIS

Hypercellularity of the bone marrow which continues to be present after the first month, is noted in mice which have been successfully treated with homologous or heterologous bone marrow. Usually, the cellularity is due to hyperplasia of the myeloid series with in addition a shift to the left, i.e. an increased number of immature cells. In some animals erythroblastosis is noted. An excessive stimulation of haematopoiesis is also suggested by the persistence of extramedullary haematopoiesis in the spleen of these chimaeras (Plate IV: 8). The myeloid hyperplasia could be easily explained by the high incidence of infection. ~~On the other hand, the possibility cannot be excluded that~~ ^{some} the remaining immunological activity on the part of the host causes increased peripheral destruction of mature donor haemopoietic cells, thereby provoking bone marrow hyperplasia, ^{some tendency to}

In the peripheral blood the outstanding feature is lymphocytopenia, which is the haematological counterpart of the atrophy of the lymphatic tissues discussed previously. ~~Secondly,~~ an absolute increase of the neutrophil count is frequently found. The neutrocytosis probably invalidates the second assumption given above, that the myeloid hyperplasia is due to increased peripheral destruction of neutrophils.

Lastly, mouse chimaeras often display an anaemia of slight or intermediate severity. This anaemia is usually accompanied by reticulocytosis, which according to one author³⁴⁹ ceases to exist after the first month, but was found to persist in our experiments. One of the possibilities is that the reticulocytosis is caused by haemolysis. In rabbit chimaeras the existence of immune haemolysis of *host* erythrocytes has been demonstrated by the application of Coomb's tests and the injection of ⁵¹Cr labelled erythrocytes^{313, 326}. Haemolytic anaemia in the first two months, could be explained, therefore, by increased peripheral destruction of host erythrocytes, which the donor erythropoietic pool is temporarily unable to compensate. Haemolytic anaemia occurring after the second month⁴⁴⁹ cannot be explained on this basis, however, since host erythrocytes are usually no longer present at that time.

The general debility of the mice suffering from secondary disease could also facilitate the development of a deficiency anaemia with reticulocytosis. This could explain the regular finding of macrocytosis in the chimaeras. It may be concluded that the question of the cause of the anaemia in certain radiation chimaeras has not yet been settled.

The thrombocyte counts in mouse chimaeras are rather variable. Slight thrombocytopenia is found in a number of animals. Especially after the transplantation of rat marrow when an unexplained thrombocytosis occurs in about one-third to one-half of the population from 30 to 130 days following transplantation.

GASTRO-INTESTINAL TRACT

Radiation induced changes of the intestinal mucosa may be seen in chimaeras shortly after irradiation. These changes are, however, of minor importance, since they never result in mucosal denudation and disappear after 5–6 days. On the other hand, important and highly characteristic lesions are found in homologous and heterologous chimaeras suffering from secondary disease. These intestinal lesions were first described in mice and subsequently discovered in human patients, monkeys, and rabbits. They have been very important in an understanding of the pathogenesis of secondary disease and the mortality of homologous or heterologous radiation chimaeras.

The lesions may take one of two forms. In the first, acute widespread crypt degeneration in the mucosa is the principal feature, while inflammatory changes are of little importance or completely absent. This form is seen in mice treated with homologous lymphoid cells which die early, 6–12 days following irradiation. Identical lesions are always found in monkeys treated with homologous or heterologous bone marrow, dying between 6 and 50 days following transplantation. Similar lesions have been described in two human patients treated with homologous bone marrow²⁶³. The presence of these severe lesions does not seem to be compatible with the survival of the individual.

The second form is a chronic inflammation of the colon and the terminal ileum and occurs in mice and rabbits treated with bone marrow. This form is probably not directly lethal—although it is the cause of persistent diarrhoea and emaciation—and it may be combated successfully in mice with antibiotics.

Acute degeneration of the mucosal crypts

The gross lesions are best described by taking as an example the appearance of the intestine of a monkey treated with homologous bone marrow.

The mucosal surface of the colon and ileum and sometimes of the entire intestinal tract is congested, moist and often covered with tightly adherent greenish-gray membranes (Plate IV: 28). Multiple small superficial erosions with a red base may be found scattered along the entire tract including the stomach.

More frequently the mucosa has a smooth surface with loss of the normal structure. The atrophy is accentuated by an unusual prominence of lymphatic follicles which appear as brownish-gray dots (Plate IV: 29). The wall of the intestine feels firm and oedematous.

Microscopically, the lesions may have a patchy distribution. In addition, the colon and ileum are usually most severely affected, although the lesions may extend sometimes to the stomach.

What appears to be the earliest phase of the lesion is widespread massive karyorrhexis and cell disintegration in the intestinal crypts (Plate IV: 30). The degenerated epithelial cells are desquamated and accumulate in the glandular lumina. This is followed by cystic dilation of the degenerating crypts, which become lined with a layer of flattened epithelium (Plate IV: 31). Between areas of crypt necrosis, crypt regeneration is usually apparent (Plate IV: 32). The hyperplastic crypts are lined with a pseudo-stratified cylindrical epithelium showing hyperchromatic nuclei and many mitoses. In the earliest and most severe lesions many crypts seem to have disappeared, until only few, widely dispersed crypts remain (Plate IV: 33). The intervening lamina propria is condensed and shows a heavy infiltration by lymphoid cells, a few plasma cells and probably some histiocytes (Plate IV: 30, 32). In the small intestine the villi are shortened or disappear completely.

Finally, the surface epithelium is lost from large stretches of mucosa, which are covered by a fibrinous membrane infiltrated by granulocytes (Plate IV: 34). In a number of cases denudation of almost the entire intestinal mucosa occurs. The submucosa shows severe oedema and is slightly infiltrated by lymphoid cells and plasma cells. Similar observations have been made in human radiation chimaeras (Plate IV: 35).

Certain aspects of the changes in the intestinal mucosa are reminiscent of radiation induced damage. Several observations are in-

compatible, however, with the assumption that radiation is the primary factor in the production of the intestinal lesions. At these dose levels irradiated control animals and animals treated with autologous or isologous bone marrow show only slight, if any, degeneration of the crypts during the first 4–6 days following the irradiation; mucosal denudation has never been observed. Moreover, in the homologous chimaeras no parallelism has been found between the extent of the lesions and the radiation dose, while the time interval between irradiation and death in these animals is appreciably longer than would have been expected if a radiation induced intestinal syndrome had been the cause of death. Finally, the preferential localisation of the lesions in the terminal part of the intestinal tract is not typically found in animals dying of the radiation induced intestinal syndrome. Experiments with mice have clearly shown that the occurrence of acute degeneration of the mucosal crypt is aetiologically related to the number of lymphoid cells injected and to the early massive proliferation of lymphoid cells in the lymphatic tissues of these mice⁴⁴³.

These observations have shown convincingly that the severe intestinal lesions which accompany early mortality after the administration of homologous lymphoid cells in mice and of bone marrow in monkeys, as well as those seen in chronic secondary disease, are primarily caused by an immunological reaction. The evidence presented in Chapter III has led to the conclusion that this is a graft versus host reaction. In addition, the acute disintegration of crypt cells in the presence of lymphoid cell infiltration suggests, as discussed previously (page 147), that the damage is the result of a direct cytotoxic effect of antibody producing cells and *not* of mitotic inhibition of the germinal crypt cells as proposed by Cole and Rosen⁸⁹.

The possibility is not excluded, however, that the irradiation might be an additional factor in the production of the described lesion. Latent radiation damage of the crypt cells could manifest itself by cell death during or after mitosis and by a shortening of the life span of the daughter cells. The loss of cells due to the graft versus host reaction would not be adequately compensated then by the increase of the mitotic frequency. Ultimately mucosal denudation would be the outcome.

Chronic ileocolitis. Chronic inflammatory changes of the intestines are seen in mice treated with homologous or heterologous bone marrow, during the period of severe diarrhoea and weight loss, i.e.

1-3 months following the irradiation. Chronic colitis has also been reported to occur in homologous rabbit chimaeras. The lesions as they occur in mice will be described in detail.

On gross examination, the coecum and ascending colon show vascular congestion and oedema. The wall is stiff and appears thickened on cross section. Microscopically, the lesions are situated in the colon and terminal ileum and usually have a patchy distribution. The intestinal crypts are separated by a dense infiltration of granulocytes, lymphocytes and plasma cells occasionally mixed with eosinophils (Plate IV: 36). The submucosa is oedematous and the lymph vessels are dilated (Plate IV: 37). The chronic inflammatory infiltration often spreads through the submucous and muscular coats in the subserosal layer. Small blood vessels at these sites may become occluded with thrombi. Scattered through the mucous membrane are crypts with a cystic appearance due to regeneration or atrophy of the glandular epithelium. Individual crypt cells show disintegration and desquamation into the lumen of the crypts. Some of the affected crypts are lined by a single layer of flattened cells (Plate IV: 38). The wall and the lumen of the glands may be infiltrated with granulocytes, creating the appearance of crypt abscesses. In some parts of the intestine, groups of crypts have, apparently, disappeared; in other parts, hyperplastic regenerating crypts are prevalent. In severe cases multiple small funnel-shaped ulcerations are seen which are covered with a fibrinous cellular exudate and these ulcerations may penetrate the mucosa as far as the muscular coat (Plate IV: 39). The severity of the lesions may vary from slight cellular infiltration of the mucosa to extensive inflammation of the entire intestinal wall with accompanying peritonitis. The widespread loss of crypts and mucosal denudation as described in the preceding paragraph is not, however, seen.

In older chimaeras atrophy of the mucosa and replacement fibrosis with slight cellular infiltration of the lamina propria may represent the healing stage although degenerating crypts may still be found scattered throughout the mucosa.

The question of the pathogenesis of these lesions initially posed a number of difficulties but the discovery of the acute syndrome in monkeys and mice has been used to arrive at a satisfactory explanation. Parallel with the much more extensive degeneration in the acute syndrome, the loss of crypts could be considered as the direct result of a graft versus host reaction. The mild crypt degeneration in itself, however, cannot be considered to be lethal. The favourable effect of

antibiotic treatment on the diarrhoea and the mortality of mice treated with foreign bone marrow suggests that bacterial infection must be an important contributory factor in the aetiology of secondary disease which appears after the first month following treatment. It could be easily visualised that the minor epithelial defects caused by the graft versus host reaction are foci of increased susceptibility to bacterial invasion. In conjunction with the general impairment of immunological defences, caused by the atrophy of the lymphatic tissues at this stage of secondary disease, widespread secondary infection of the intestines can easily develop.

This view has been amply confirmed by recent studies of germ-free mice treated with rat-bone marrow (D. W. van Bekkum, D. van der Waay and M. J. de Vries. *J. Exp. Hematol.* (1965) 8, 3-5). In these mice crypt lesions were clearly present while there was a complete lack of the inflammatory component which dominates the lesions in conventional chimaeras (Plate IV: 39(a)).

After about the third month the mortality and the incidence of diarrhoea diminish sharply. Examination of surviving chimaeras at this time has revealed that in certain relatively incompatible host-donor combinations minor lesions of the crypts persist, although the inflammatory changes are minimal. The lymphatic tissues of these animals are partly or completely regenerated. The latter fact points to the development of a partial immunological tolerance of the graft towards the host, as has been discussed in the previous chapter. With the advent of the regeneration of the lymphatic tissue the immunological defence against micro-organisms apparently recovers, enabling the animal to combat secondary infection of the intestinal lesions.

Incidentally, it may be noted that the chronic ileocolitis of secondary disease has some morphological features in common with chronic ulcerative colitis in man. One can only speculate about the possible aetiological relationship of these two diseases, especially since an auto-immune reaction has been postulated as the cause of the human disease.

LIVER

In the literature, necrosis of the liver is among the earliest and most frequently reported lesions in radiation chimaeras in all the species so far investigated. The characteristic lesions must be differentiated from septic necrosis, which can occur in irradiated non-treated animals and after the rejection of a foreign bone marrow graft.

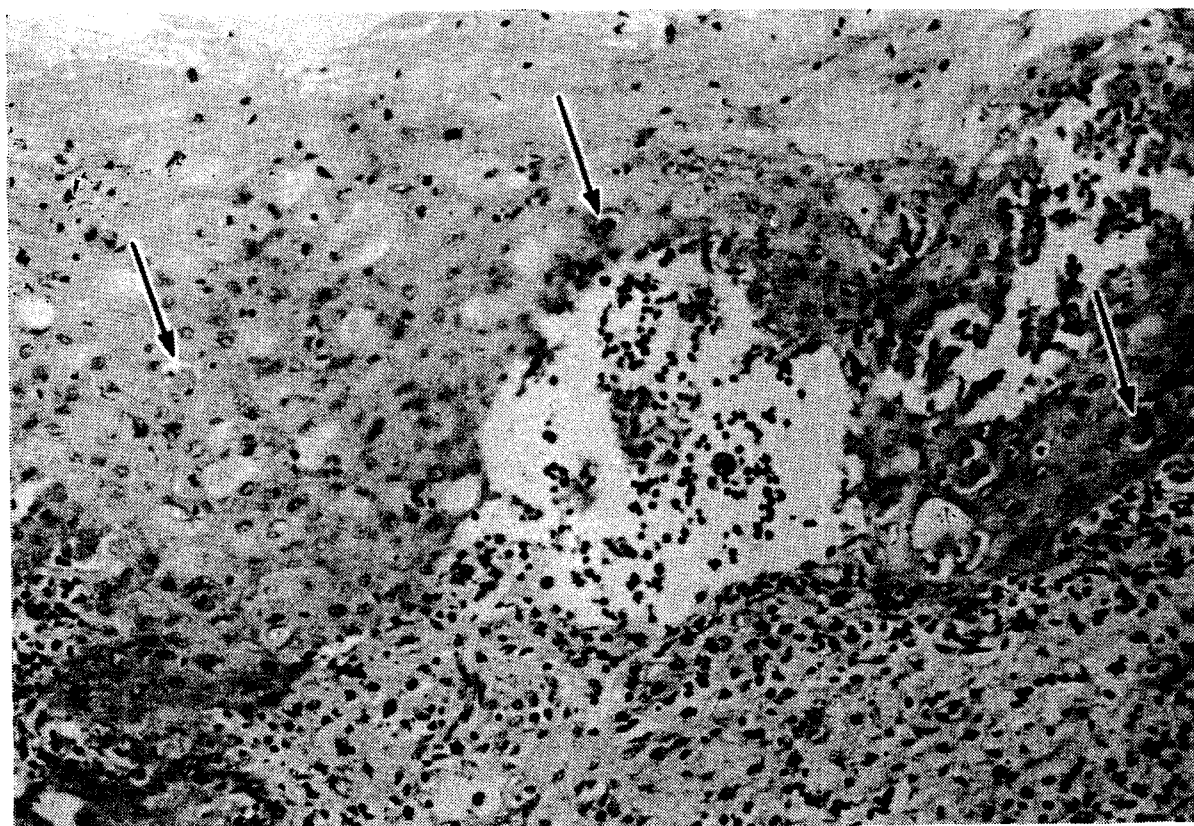


PLATE IV: 52. Squamous epithelium of oesophagus of homologous monkey chimaera (7 days) showing changes similar to those of the epidermis in secondary disease: infiltration by lymphoid cells, vacuolar degeneration with bulla formation and scattered necrotic cells ("dyskeratosis", see arrows). (HE).
Magnification $\times 220$

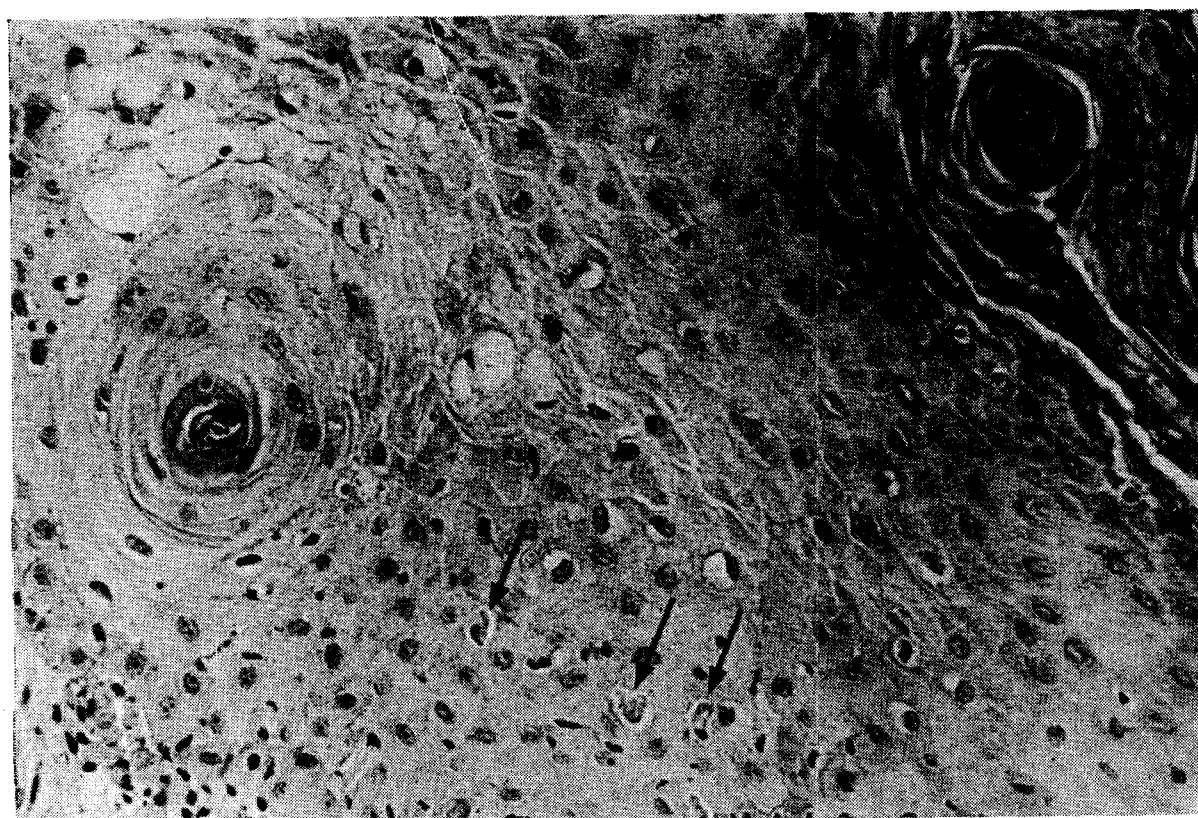


PLATE IV: 53. Rejection of a human skin homotransplant, biopsy taken on day 8. Acanthosis, parakeratosis (upper right), dyskeratosis (arrows) and vacuolar degeneration in malpighian layer. The epidermis is sparsely infiltrated with lymphoid cells. (HE). Magnification $\times 190$

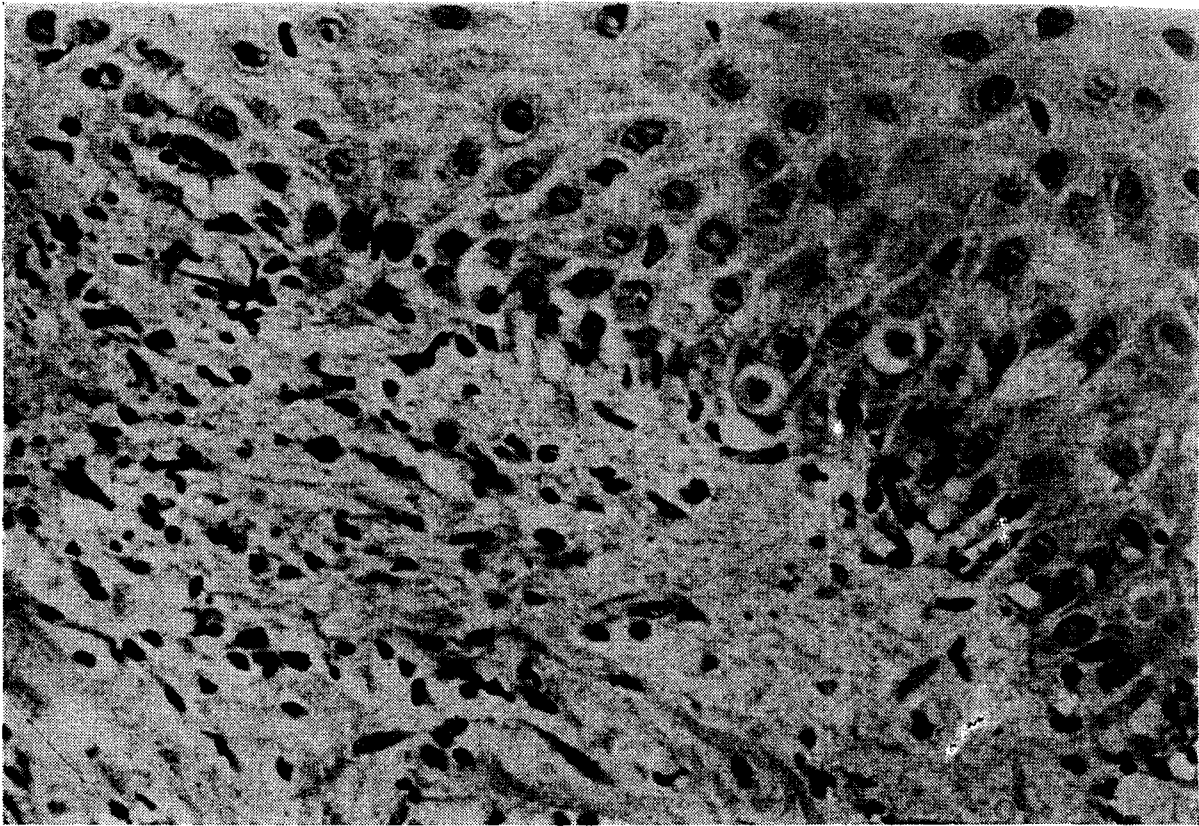


PLATE IV: 54. Rejection of a human skin homotransplant, biopsy taken on day 6. Lymphoid cell infiltration of corium and base of epidermis, basal cell vacuolisation. (HE). Magnification $\times 190$

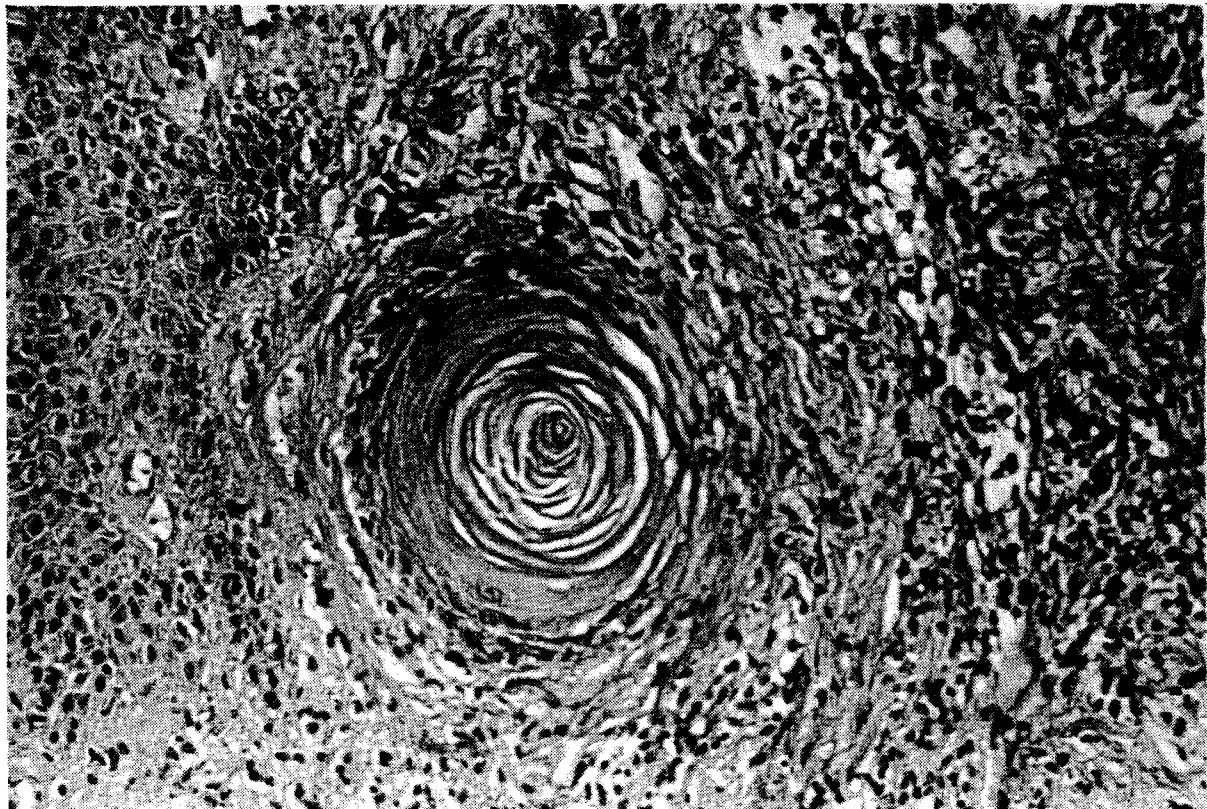


PLATE IV: 55. Rejection of a human skin homotransplant, biopsy taken on day 12. Hair follicle plugged with keratin (follicular hyperkeratosis). (HE). Magnification $\times 190$

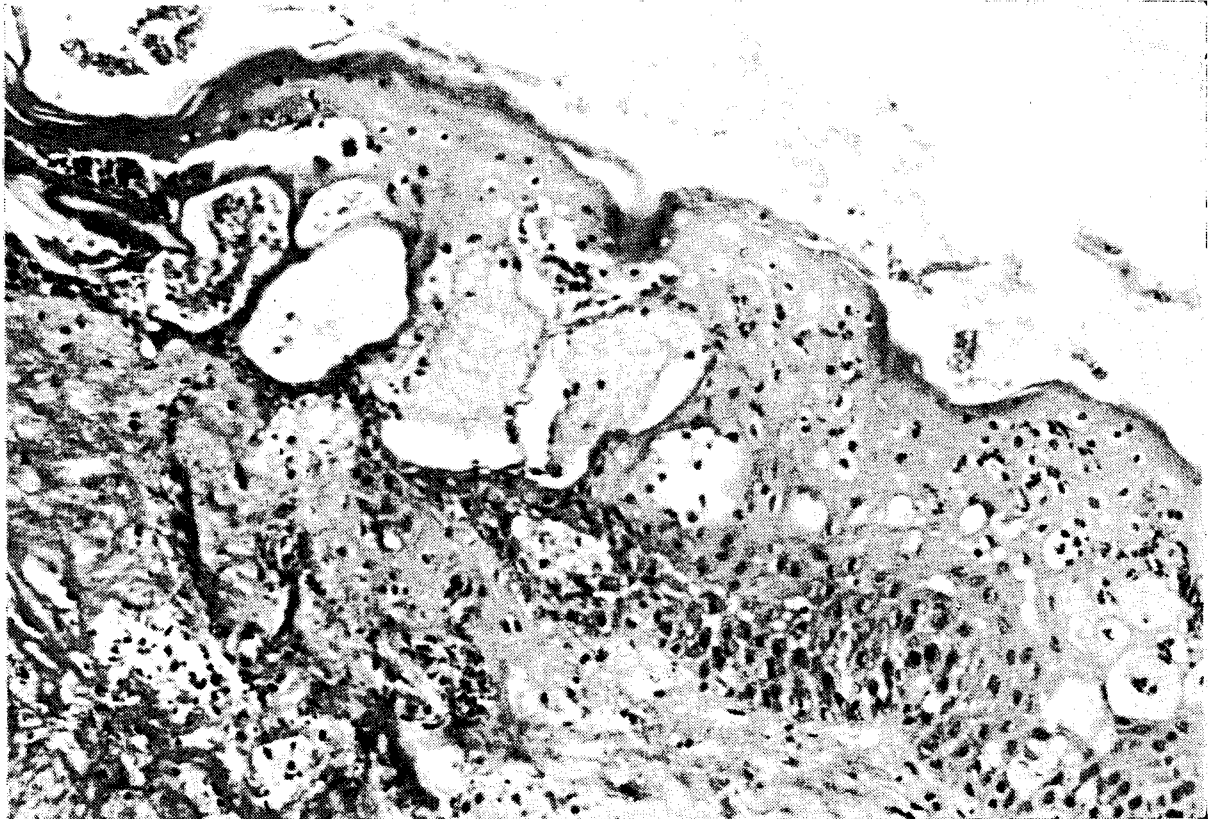


PLATE IV: 56. Rejection of a human skin homograft, biopsy taken on day 9. Lymphoid cell infiltration, vacuolar degeneration with bulla formation, parakeratosis (upper left). The superficial layers of the epidermis are necrotic. (HE). Magnification $\times 120$

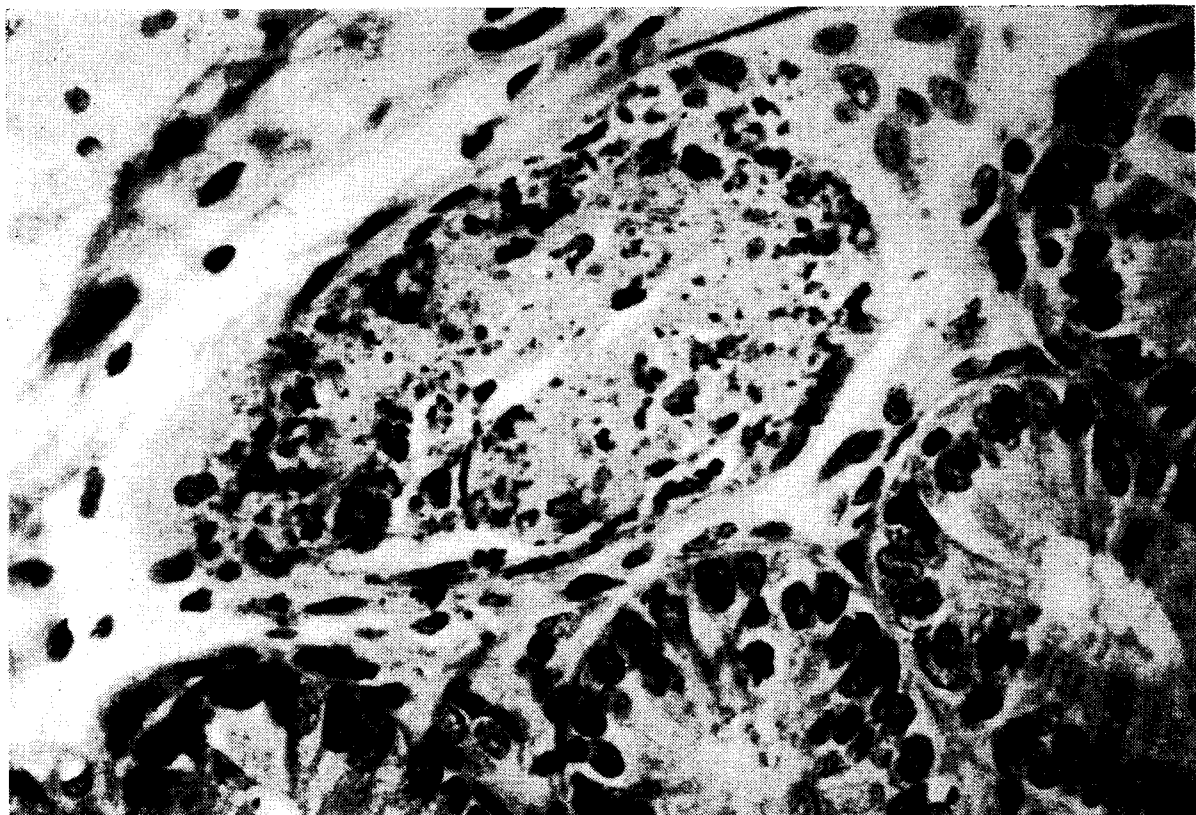


PLATE IV: 57. Arteriolar necrosis in submucosa of colon of homologous mouse chimaera (17 days). (HE). Magnification $\times 480$

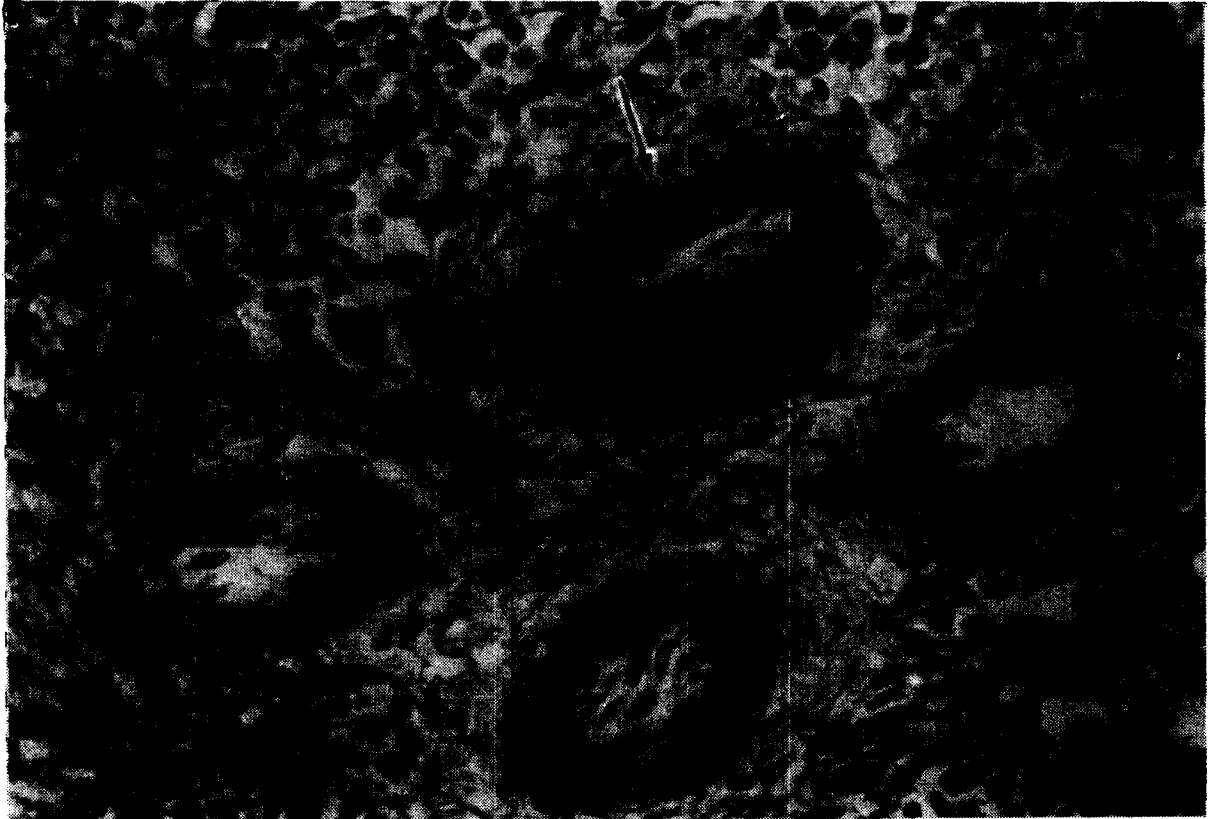

PLATE IV: 58. Subendothelial deposition of PAS-positive fibrinoid material in splenic arteriole (arrow) of human radiation chimaera (lethally irradiated leukaemic child treated with homologous bone marrow). Photograph from Mathé *et al.* (1960)²³⁶. (Periodic acid Schiff.) Magnification $\times 120$

In septic necrosis both the parenchymal cells as well as the stromal cells are affected (Plate IV: 4), and masses of bacteria are usually found in the centre of the lesions. Furthermore, there is a conspicuous lack of a leucocytic inflammatory response to the infection in lethally irradiated animals that have not been treated with bone marrow.

In secondary disease the lesions are restricted to the hepatic cells and the bile duct epithelium. In the less severe cases degenerated liver cells, which show cytoplasmic eosinophilia and nuclear pyknosis are sparsely disseminated throughout the liver lobules (Plate IV: 14). Eosinophilic globules resembling Councilman bodies represent cells which have undergone lysis of the nucleus. The epithelium of the smaller bile ducts may be swollen, thereby almost obliterating the lumen, whilst the epithelial cells of these ducts display cytoplasmic eosinophilia and pyknosis (Plate IV: 40).

Many mitotic figures of both the liver cells and the bile duct epithelium are found. Some of these show various mitotic aberrations probably due to irradiation damage.

In the more severely affected livers, the changes are readily visible. The surface and cross sections show multiple ill-defined pale-gray areas, with loss of lobular structure. The liver may be reduced in size and softer than normal. In mice, the liver surface may exhibit a peculiar variegated aspect, with an alternation of red coloured depressions and slightly elevated yellow-to-gray areas.

Microscopically, multiple foci of disruption of liver cell cords and necrosis are seen (Plate IV: 41). The parenchymal dissociation may involve whole liver lobules. Foci of overt necrosis are seen mainly periportally, but they may also have a pericentral or midzonal localisation. In a number of cases large areas of liver necrosis are present in which the supporting connective tissue is condensed and the hepatic sinusoids are dilated (Plate IV: 42). The periportal connective tissue is usually moderately infiltrated with lymphoid cells and histiocytes. In mice extensive myelopoiesis is frequently present. The proliferation of fibroblasts and bile duct structures is noticed in what appear to be the later stages of the lesion.

Lastly, the occurrence of a pronounced histiocytic reaction must be mentioned (Plate IV: 43). The significance of this reaction, which has been mainly observed in mice and rats, may be similar to the histiocytic infiltration of lymph nodes described earlier. The liver cell cords are separated by large numbers of cells with oval, indented or elongated nuclei and an eosinophilic cytoplasm. The infiltration

often extends through the liver lobule into the wall of a central vein and seems to be the cause of atrophy of liver cell cords.

It is noteworthy that in all species the liver lesions have to be differentiated from natural occurring infections: viral hepatitis in man, monkey, dog and mouse, coccidial infection in rabbits and Tyzzer's disease in mice.

Since the lesions resemble those of hepatitis the possibility that an activated virus infection is an aetiological factor has been considered. Although inclusion bodies have been found in dogs, they have not been seen in mice and only exceptionally in homologous monkey chimaeras. In mice and monkeys, irradiation only, or treatment with autologous or isologous bone marrow, does not cause comparable liver lesions. The very rapid development of similar lesions in newborn mice injected at birth with homologous lymph node cells, or in monkeys treated with bone marrow—i.e. cases in which the anti-viral defences are presumably not jeopardised by lymphatic tissue atrophy—also suggests that a graft versus host reaction may be primarily responsible.

In mice, infection with *Bacillus piliformis* (Tyzzer's disease) has been considered as the cause of the hepatic lesions. During epidemics of the disease, the causative agent can be detected easily in the liver lesions of mice dying of this infection. However, in an extensive search for the organism in mouse chimaeras, using PAS-stained liver sections the characteristic intracellularly located slender rods could not be detected. Moreover, the presence of similar liver lesions in germ-free mice treated with rat-bone marrow, does not favour an infectious aetiology (D. W. van Bekkum, D. van der Waay and M. J. de Vries: *J. Exp. Hematol.* (1965) 8, 3-5).

JAUNDICE

Jaundice is frequently found in homologous monkey chimareas. Since it has not been observed so far in irradiated non-treated monkeys, nor in monkeys treated with autologous bone marrow, the condition seems to be somehow related to the chimaeric state. The jaundice might be caused by hepatic cellular damage. One argument against hepatocellular jaundice is the fact that liver necrosis may be present without jaundice and *vice versa*.

Another possibility is that the described degeneration and swelling of epithelium of the bile ducts results in obstructive jaundice. Finally, haemolysis of either host- or donor-type erythrocytes as discussed in a

previous section must be considered. Which of the factors or combination of factors mentioned is in fact responsible remains to be settled.

SKIN

A generalised dermatosis is so regularly found in radiation chimaeras, that it may be considered as highly pathognomonic of secondary disease. In addition, the morphological alterations of the skin provide strong evidence in favour of the immunological nature of secondary disease since they are very similar to the lesions seen in the reverse condition, namely, the rejection of a skin homograft by a normal host in which irradiation is not involved as a complicating factor.

Each of the morphological features which will be discussed below have been described in conjunction with experimental and clinical skin grafting, especially when the rejection has been slow. This is the case when grafted isologous male skin is rejected by female mice of certain strains, when histo-incompatibility does not involve the strong H₂ antigen in mice, or when homologous skin is grafted in hamsters. This similarity leads to the attractive assumption that, although ultimate sloughing of the epidermis is rarely seen in chimaeras, except in rats treated with homologous lymphoid cells, the whole skin of the host is actually being slowly rejected by a functioning transplant of immunologically competent cells of donor origin.

The macroscopical appearance of the early lesion has been best observed in monkeys and man. A macular erythema appears on the skin of the face, at first surrounding the orbits and the mouth and spreading to the trunk and arms (Plate IV: 48). In the days following, coalescence of the individual maculae may lead to the appearance of a diffuse erythrodermia. The skin is warm, dry and appears infiltrated and oedematous. In human cases the development of bullae which may rupture and leave a denuded epidermis, has been described. Following the erythrodermic phase extensive dry scaling occurs which also begins on the face and ears (Plate III: 5). Characteristic is the widening and protrusion of the orifices of the hair follicles which are plugged with horny substance. Ulceration or fissuring of the skin is sometimes found and ultimately total desquamation of the epidermis may occur. This has been frequently observed in rats, especially when treated with homologous lymphoid cells.

In mice the fur has a characteristic ruffled appearance and epilation is often seen (Plate III: 2). In older mouse and rat chimaeras

the skin may be appreciably thickened and have a parchment-like consistency.

The microscopic appearance of the skin in the early erythematous phase has not been studied adequately, because the chimaera usually dies in the second and desquamative phase. The latter lesions are microscopically similar in mice, monkeys, and man.

Hyperplasia of the epidermis is the most conspicuous feature (Plates IV: 15 and IV: 44 should be compared with Plate IV: 45 of normal monkey). The acanthosis involves the hair follicles which may be surrounded by broad mantles of epithelium. Hyperkeratosis with distension of the follicles by accumulated horny substance—follicular hyperkeratosis—explains the extensive scaling of the skin. Localised persistence of nuclei sometimes in rounded masses—parakeratosis—may be found in the horny layer (Plates IV: 46 and IV: 47).

Dispersed between the epithelial cells of the epidermis and the hair follicles are numerous rounded cells with a homogeneously eosinophilic cytoplasm and a pyknotic or disintegrating nucleus (Plates IV: 16, IV: 44 and IV: 49). These dyskeratotic cells appear isolated or in small collections and may even be found between cells of the basal layer.

Also very characteristic, and frequently seen in chimaeras of all species, is liquefaction degeneration of cells of the basal layer of the epidermis. Rows of vacuoles are seen on the margin of the epidermis and corium, sometimes accompanied by separation of epidermis and corium (Plates IV: 47 and IV: 50). Other degenerative features are the total disappearance of the basal cell layer and a vacuolar degeneration of cells of the stratum spinosum (Plate IV: 46). In rats total necrosis of the epidermis and the underlying corium may be seen (Plate IV: 51).

In some cases, the hair follicles may show signs of atrophy instead of hyperplasia, the follicular remnants being covered with a few layers of pale, swollen epithelial cells (Plate IV: 46).

In the epidermis or superficially in the corium, globular structures consisting of concentrically layered, flattened epithelial cells may be seen in monkeys and in man. It is supposed that these represent a metaplastic change in the excretory ducts of the sweat glands.

The corium and subcutis show intercellular oedema and are infiltrated to a varying degree with lymphocytes, histiocytic cells, plasma cells and occasionally with granulocytes. The cellular infiltra-

tion often surrounds the hair follicles, sweat glands and small vessels and penetrates between the epithelial cells of the appendages and the epidermis (Plates IV: 16, IV: 44, IV: 46, IV: 49 and IV: 50). Sometimes a granulomatous reaction with the appearance of multinucleated giant cells is seen in the vicinity of remnants of disintegrated hair follicles. In later phases, the cellular infiltration diminishes and an increased number of fibroblasts in the corium is noted. In older mouse chimaeras the epidermis may be reduced to a few cell layers and the number of hair follicles appears to have decreased. Below the atrophic epidermis the corium shows some fibrosis.

The similarity of the skin lesions in secondary disease and the skin changes during a homotransplant rejection is clearly brought out by comparing the described lesions with Plates IV: 53 to IV: 56, taken from biopsies of human skin homografts.

It is noteworthy that epithelial changes resembling those of the skin have been observed in the oesophagus of a few monkeys (Plate IV: 52).

KIDNEYS

The kidney lesions found in chimaeras are of minor importance and are probably not specific. Albuminous degeneration of the convoluting tubules with albuminous casts in the collecting tubules is regularly observed in monkeys treated with homologous bone marrow. In a few cases a number of convoluted tubules scattered throughout the cortex showed distinct necrosis of the epithelium. Strongly eosinophilic hyaline and granular casts, partly surrounded by multinuclear cells, probably derived from desquamated tubular epithelium, have been found in the collecting tubules. Glomerular and vascular changes were not apparent.

The renal tubular changes have not been attributed to the direct effect of the graft versus host reaction and can be explained by secondary effects, such as shock, anoxia, haemolysis or hepatic damage.

CARDIOVASCULAR SYSTEM

There is little evidence that vascular changes are of great importance in secondary disease. This is of particular significance in a consideration of whether secondary disease is morphologically allied to the collagen diseases and the so-called allergic diseases in man (lupus erythematoses, periarteritis nodosa, allergic arteritis and others) as discussed in a later section.

In the CBA mouse strain, animals dying from secondary disease may display severe calcification of the cardiac musculature. This process is probably related to inanition or other sequelae of the severe debilitation of the mice, because it likewise occurs in irradiated non-treated mice but not in irradiated mice treated with isologous bone marrow, where comparable debilitation is absent.

A generalised necrotising arteritis, mainly affecting arterioles and capillaries, but sometimes also larger arteries, has been observed in a number of mice treated either with homologous or heterologous bone marrow after a minimum LD₁₀₀ dose of radiation (Plate IV: 57). The affected vessels were strongly stained by the PAS method and showed nuclear fragmentation in the muscular coat. The endothelium was swollen and sometimes the lumen was occluded by a thrombus. The vascular wall and adventitia were often infiltrated with lymphoid cells, plasma cells and granulocytes.

The lesions occurred in the first month following the irradiation, during the period of maximum incidence of graft rejections and before the appearance of secondary disease. In a few mice septicaemia coincided with the vascular alterations. These observations suggest that the vascular lesions are either septic in origin or are related in some other way to the graft rejection. The latter possibility is supported by the observation that necrotic changes in small vessels, accompanied by thrombosis and deposition of fibrinoid substance, have been observed in mice at the end of the first week following irradiation with midlethal doses and injection of homologous bone marrow.

In monkeys vascular changes have not been observed. In two of Mathé's young patients, who both died following a take of a homologous bone marrow transplant, massive deposition of fibrinoid substance in the wall of small arterioles in the spleen was a striking feature (Plate IV: 58). The accumulations of fibrinoid material apparently caused the obliteration of the vascular lumina which in turn explained the development of multiple foci of haemorrhagic infarction. Vascular necrosis was not apparent, however, nor were vascular changes found in other sites.

OTHER ORGANS

Isolated degeneration of cells accompanied by an increase of mitotic frequency, as discussed in the section on general pathology, has been observed in the adrenal cortex, the pancreatic acini as well

as the islet tissue, the salivary glands, and the transitional epithelium of the renal pelvis.

Of the other endocrine glands, the thyroid has been examined in a few monkeys treated with homologous bone marrow. No apparent abnormalities could be detected.

The central nervous system was studied in a series of mice treated with homologous bone marrow and lymph node cells. Pathological changes were not apparent in sections routinely stained with haematoxylin and eosin.

In cross-striated muscle tissue of mice and monkeys sarcosporidiosis was sometimes noted. Lesions which could be attributed to secondary disease were not, however, found.

In the testes of mice treated with homologous or heterologous bone marrow, recovery of spermatogenesis was generally delayed in comparison to mice treated with isologous bone marrow. This might be attributed to the debilitated condition of the mice. Ovaries were examined in a few monkeys treated with homologous bone marrow. No differences were apparent between these monkeys and those irradiated and not treated, or monkeys irradiated and treated with autologous bone marrow.

The causes of death in secondary disease

As has been discussed in previous sections, secondary disease may manifest itself as an acute illness with early mortality, or as a chronic illness from which the animals die relatively late in the course of the disease. The direct causes of death may be different in both syndromes.

In the chronic protracted phase of secondary disease, which occurs in mice treated with bone marrow, the animals usually die showing signs of a generalised infectious disease. As for instance with pneumonia, this may be responsible for the death of many chimaeras. One of the most commonly found conditions in these animals is chronic ileocolitis. It is probably this infectious complication which is responsible for the progressive clinical deterioration and wasting of the chimaeras. Significant in this respect is the fact that both the mortality and the wasting can be largely prevented by treatment with antibiotics. One of the factors which could explain these effects of the chronic colitis might be a continuous loss of protein. This has been investigated by Friedberg¹⁴⁶ who injected human serum albumin labelled with ¹³¹I into lethally irradiated mice treated with rat bone

marrow. He concluded that an increased fractional rate of loss of endogenous serum albumin occurred in these chimaeras, which he ascribed to increased catabolism (presumably due to infection, immunological processes, etc.) or leakage of the protein through the damaged intestinal mucosa.

Other factors, such as anorexia and the continuous immunological destruction of cells, may contribute to this state of uncompensated catabolism, leading to a general debilitation and death, even in those cases in which there is no complicating secondary infection.

It can be concluded that in the chronic late phase of secondary disease the graft versus host lesions in themselves are usually not of sufficient severity to explain the mortality and that death must have been caused by a number of partly still ill-defined complications.

In contrast, death of the chimaeras in the early, acute phase of secondary disease can much more easily be ascribed to the direct effects of the graft versus host reaction: intestinal denudation, hepatonecrosis and diffuse disintegration of cells in other vital organs. Acute denudation of large stretches of the intestinal mucosa may lead to shock from dehydration, disturbance of electrolyte metabolism and loss of protein. It also seems possible that shock could be induced by endogenous intoxication from the toxic products formed in the acute generalised destruction of cells.

In a comparatively small proportion of animals, death is readily explained by the extensive morphological damage of the liver. Whether haemolysis is a factor of importance in the production of mortality in the acute syndrome has not been adequately evaluated. As has been discussed in a preceding section, the jaundice which is frequently present in monkey chimaeras might have been caused by haemolysis. An argument against the interpretation of haemolysis as a lethal complication is that severe haemoglobinuric nephrosis is rarely seen in these animals. On the other hand, massive acute haemolysis could have caused death from shock before the development of such renal lesions.

*Comparison of secondary disease with runt disease
and homologous disease*

Haemopoietic chimaerism may be attained without the aid of irradiation by taking advantage of the immunological immaturity of newborn animals of certain species or the inability of the F_1 to react against parental antigens.

Mice and rats injected at, or shortly after birth, with adult homologous haemopoietic cells fail to grow at a normal rate and may show one or more of a variety of clinical symptoms: emaciation, stunting, a hunched appearance, ruffling of the fur, thickening of the skin and diarrhoea^{62, 66, 375, 376}. Death may occur within 4 weeks. This condition is called "runt disease". A similar disease develops after hatching in chickens, the embryos of which were injected with adult homologous spleen cells⁶² or again after parabiotic union with another embryo³⁷². Adult F₁ mice injected with parental lymphoid cell suspensions likewise develop a runting syndrome, denoted as homologous disease⁴¹⁷.

As has been described earlier, these syndromes are the outcome of an immunological reaction of the foreign cells against the host. It is of considerable interest that the pathological changes, as described in animals suffering from runt disease and homologous disease^{1, 66, 162, 385}, are very similar to those found in secondary disease. A possible exception are the intestinal lesions, which have not been reported *in extenso* although diarrhoea is apparently often present. A study of mice suffering from runt disease by the present authors has shown that degeneration of crypts occurs in a proportion of cases, although it is less severe than that found in radiation chimaeras; denudation of the mucosa is absent. One of the explanations for this might be that, the other abnormalities seen in runts prove lethal before significant intestinal changes can develop. On the other hand, the radiation could be an important secondary factor in the production of these lesions in radiation chimaeras.

Profound haematological abnormalities are present in runts as well as in animals suffering from homologous disease^{297, 372}. Haemolytic anaemia with high reticulocyte counts and a positive antiglobulin test occurs regularly. Acute haemolysis with jaundice has been observed occasionally. In rats the anaemia may be of an aplastic type⁶⁶. Other abnormalities are neutrocytosis, lymphopenia and thrombopenia. These data point either to an increased destruction of mature peripheral blood cells or to destruction of the immature precursors in the bone marrow or to the two conditions together. Both result from the activity of the grafted immunologically competent donor cells.

In the lymphatic tissues atrophy of the lymphatic follicles, sometimes accompanied by necrosis, is an important feature of runt disease. Contrary to what is generally found in radiation chimaeras, and

in spite of the lymphoid atrophy, the animals show an enlargement of spleen and lymph nodes, which is caused by an intense proliferation of reticular cells, histiocytes and plasma cells. In the liver a similar cell infiltration is found in the portal triads and in the sinusoids between the liver cell cords. When this infiltration is pronounced, the liver cords show atrophy and dissociation. Foci of necrotic liver cells surrounded by histiocytes may be found. In addition, many mitoses of liver cells and an increase of haemopoiesis are seen. The question is, once again, whether the histiocytic cells are the cause of the cell destruction or merely scavenger cells engaged in the clearing away of dead cells. According to our own observations, the destruction of liver cells is found much more frequently in runts than in radiation chimaeras.

The skin changes have been examined extensively in runted rats by Billingham and his group⁶⁶ and in rats suffering from homologous disease by Stastny and co-workers³⁸⁵ and are closely similar to those observed in secondary disease.

It may be concluded that the graft versus host reaction causes a number of highly characteristic lesions which are found both in runt disease and homologous disease, as well as in secondary disease in a variety of animal species.

Graft versus host diseases and auto-immune diseases

In a number of human diseases, among them the so-called collagen diseases, auto-antibodies have been demonstrated which are directed against a large variety of antigens contained in cells (erythrocytes, leucocytes, thrombocytes, cell nuclei) and tissues (brain, colon, kidney, liver, striated muscle) and against antigenic cell products (γ -globulin, thyroglobulin, lens proteins). Formation of such auto-antibodies may be accompanied by either an organ localised auto-immune disease with the lesions confined to the particular organ or tissue in which the antigen is present, e.g. auto-immune thyroiditis, or with a more generalised auto-immune disease with lesions spread throughout many organs and tissues.

Since the cellular antibodies in graft versus host diseases are also directed against host antigens, it is reasonable to speculate whether these diseases could represent an experimental model for human auto-immune disease. Oliner and co-workers²⁹⁷ have postulated such a model for mice treated with parental spleen cells because of the occurrence of splenomegaly and certain haematological abnormalities:

haemolytic anaemia with a positive Coombs test, leucopenia and thrombocytopenia. Similarly, by an investigation of adult tolerant rats treated with homologous spleen cells, Stastny and co-workers arrived at the conclusion that the skin lesions presented by the animals mimicked those of human lupus erythematoses and scleroderma and that a common pathogenesis could therefore be postulated.

On the other hand, a number of differences between a graft versus host disease and an auto-immune disease are apparent. The similarities and dissimilarities will therefore be summarised.

GENERAL FEATURES

Fibrinoid necrosis of collagen and of blood vessels is a universal feature of the generalised auto-immune diseases—e.g. lupus erythematoses, polyarteritis nodosa and rheumatoid arthritis—but is found only rarely in graft versus host disease. Although this change has been described by Stastny^{385, 386}, it should not be forgotten that his rats were treated with exceptionally large numbers of spleen cells (200–800 million).

Until now the LE-cell phenomenon and the occurrence of haematoxylin bodies in the tissues have not been reported in graft versus host diseases. Certain autoimmune diseases are frequently accompanied by hyperplasia of the thymus and the other lymphatic tissues with the formation of lymphatic nodules in the medulla of the thymus. In graft versus host disease, on the other hand, atrophy of the lymphatic tissues is frequently found whilst lymphatic nodule formation in the thymic medulla does not occur.

Among the similarities are the previously mentioned haematological phenomena, splenomegaly mainly caused by extramedullary haemopoiesis, and possibly hypoplasia or atrophy of the lymphatic tissues in the terminal stages of the disease. Interestingly, the lesions of graft versus host diseases, as well as those of auto-immune diseases, show a constant association of infiltration of the diseased tissues by lymphoid cells with desquamation of the cells of these tissues.

ORGAN- OR TISSUE-SPECIFIC FEATURES

In the generalised auto-immune diseases the blood vessels, the heart, the joints and the serous membranes are frequently affected. Necrotising arteritis, nephritis, myocarditis, endocarditis, arthritis and serositis are rare in graft versus host disease, although the occurrence of endocarditis, myocarditis and polyarthritis has been

described in rats suffering from homologous disease after treatment with very large numbers of homologous spleen cells³⁸⁶.

Lesions of the thyroid, adrenal, striated muscle, ocular tissues, brain and testis, similar to those found in organ-localised auto-immune disease, have not been reported in graft versus host disease. In graft versus host disease the absence of such lesions might be explained by the existence of a blood-tissue barrier, which prevents the circulating donor lymphoid cells from gaining access to the particular organ-specific antigens. In organ-localised auto-immune disease it is assumed that this barrier is primarily disturbed, causing otherwise "shielded" antigens, to which the immunological apparatus is not tolerant, to appear in the general circulation.

One other human disease which is considered to be possibly of an auto-immunological nature, has to be mentioned here: colitis ulcerosa. The features of human ulcerative colitis are reminiscent in several respects of the chronic colitis of mice treated with foreign bone marrow: subacute to chronic inflammation of the mucous membrane, multiple superficial ulcerations, crypt destruction and oedema and lymph stasis in the submucosa. It is attractive to postulate that the pathogenesis of both forms of colitis is similar and that immune or auto-immune damage of crypt epithelium leads to small mucosal defects, which are secondarily infected by the intestinal flora.

As already mentioned, the skin changes in graft versus host disease have some characteristics in common with those in lupus erythematoses. Lupus erythematoses is characterised by either acanthosis or atrophy of the malpighian layer of the epidermis and hair follicles, hyperkeratosis with keratotic plugging of the hair follicles, liquefaction degeneration of the basal cells and a lymphocytic infiltrate in the dermis in the vicinity of the dermal appendages; these characteristics are nearly always present in graft versus host diseases. However, fibrinoid degeneration of the dermal collagen is frequently found in the acute and sub-acute forms of lupus erythematoses, but only rarely in graft versus host disease. On the other hand the dyskeratosis of epidermal cells which is a highly significant change in graft versus host disease is far less conspicuous in lupus erythematoses. It has been mentioned before that a number of visceral lesions characteristic of disseminated lupus erythematoses, i.e. lesions of the heart, serous membranes, arteries and the kidneys are only rarely present in graft versus host disease.

It may be concluded, therefore, that although graft versus host

disease and auto-immune disease have an immunological basis, care must be taken before an identical pathogenesis for the lesions is accepted.

Graft versus host diseases and the immunological deficiency syndromes

The decreased resistance of radiation chimaeras to infections, which is the main cause of mortality in mice treated with foreign bone marrow, has induced many authors to compare secondary disease with a number of clinical or experimentally produced "immunological deficiency syndromes".

In patients suffering from congenital or acquired agammaglobulinaemia and in essential lymphopenia⁴⁰⁹, either atrophy of the lymphatic tissues or a defect in the production of plasma cells and gamma-globulins is at the root of a generalised susceptibility to infections. The immunological defect in agammaglobulinaemics is further underlined by the fact that homotransplants of skin show prolonged or occasionally even indefinite survival in these patients¹⁵⁸.

It was mentioned in Chapter III that Loutit²³³ has postulated that a primary defect in lymphocyte production is the common aetiological factor in all graft versus host diseases. Although lymphatic tissue atrophy is the main cause of death in some forms of graft versus host disease, it has been pointed out already in a preceding section of this chapter that this atrophy is a secondary complication of the graft versus host reaction. Furthermore, in other forms of graft versus host disease, infection plays a minor role. Symptoms, lesions and death are a direct consequence of the graft versus host reaction. Loutit's theory seems to have been supported, however, by the observation that an experimentally produced wasting disease, induced by neonatal thymectomy in rodents, closely resembled clinically the wasting caused by the graft versus host reaction, although no such graft is present in thymectomised animals.

The wasting in neonatally thymectomised rodents may be accompanied by diarrhoea and skin lesions. From the earlier investigations of Miller *et al.*²⁸¹ a primary defect in the development and maturation of the lymphatic tissues was at first held responsible for this wasting disease. Recent studies prove, however, that in the thymectomised animal initial development of the lymphatic tissues precedes a secondary disintegration and atrophy⁴⁴⁷. Apart from this finding a number of other lesions in these mice are very similar to those found in graft versus host reactions.

In the lymphatic tissues and the liver a pronounced histiocytic reaction is apparent. This reaction and an intense plasmocytosis explains the enlargement of the lymph nodes in certain stages of the wasting syndrome. Diffuse isolated degeneration of liver cells and sometimes extensive necrosis of the liver may be present. Focal disintegration of the crypts occurs in the small and large intestines and is reminiscent of the intestinal lesions of chronic secondary disease in mice. Acanthosis accompanied by focal parakeratosis and vacuolisation of basal cells has been observed in the skin although dyskeratosis is rarely seen. In some cases atrophy of the epidermis accompanied by fibrosis of the dermis has been noted.

These skin changes, apart from bearing a resemblance to those seen in secondary disease, are reminiscent of lupus erythematoses, a human auto-immune disease. Interestingly, other lesions found in the human disease were discovered in thymectomised mice. In the kidney, fibrinoid necrosis of glomerular capillaries as well as the wire-loop change, a characteristic pathological feature, were repeatedly found. Foci of fibrinoid necrosis in the myocardium and endocardium with deposition of thrombi on the endocardial surface have been observed and it may be recalled that these changes are common in the heart disease in human lupus. In L.E.-cell preparations of the blood of thymectomised mice, typical L.E. cells have not been found till now, but rosette-like configurations of leucocytes, containing inclusions reminiscent of agglutinated and changed thrombocytes, were found in a few cases. In one of the mouse strains tested, positive Coomb's tests associated with anaemia were observed in a significant number of the wasted mice.

On the basis of these findings it has been postulated that neonatal thymectomy in mice may induce an experimental auto-immune disease, possibly by a defect in the self-recognition mechanism, caused by the absence of the thymus⁴⁴⁷. Secondary atrophy of the lymphatic tissues ultimately occurs, presumably by a mechanism similar to that described for animals with graft versus host disease, the so-called "allergic death" of immunologically competent cells. The secondary depletion of lymphoid cells would then account for the extraordinary susceptibility of neonatally thymectomised mice to infections, especially to viral disease.

It appears, therefore, that the pathology of the post-thymectomy syndrome lies somewhere intermediate between that of graft versus host syndromes and human auto-immune diseases, sharing features

with both groups of diseases (Table IV: 1). From the findings in thymectomised mice it is tempting to speculate whether, in certain human immunological deficiency diseases, some primary process leads to lymphatic tissue depletion. This, as yet, unknown process might well be of an auto-immune nature.

Whatever may be the true relation between the experimental and the human diseases, the discovery of the graft versus host reaction offers many new experimental approaches to the study of auto-immunity in man.

TABLE IV: 1. Pathology of graft versus host reactions, thymectomy syndrome and human autoimmune disease

	Graft vs. host	Thymectomy	Lupus erythematodes
Splenomegaly	+	+	+
Liver necrosis	+	+	Lupoid hepatitis?
Intestinal lesions	+	+	Colitis ulcerosa?
Skin			
Acanthosis, hyperkeratosis parakeratosis	+	+	+
Dyskeratosis	+	±	—
Basal cell vacuolation	+	+	+
Focal necrosis corium	+	+	+
Wire loop kidney	—	+	+
Endocarditis	—	+	+
Arteriolar changes	+*	—	+
Spleen			
Histiocytic and plasmocytic reaction	+	+	+
Lymphocyte disintegration	+	+	+
Anemia, neutropenia, Lymphopenia, Thrombopenia			
	+†	+	+
L.E.-cells	—	±‡	+

* Man

† Runt disease

‡ Rosettes with atypical inclusions