

Prelymphoma, Early Lymphoma, and Manifest Lymphoma in Immunosialadenitis (Sjögren's Syndrome) – A Model of Lymphomagenesis

K. Lennert and U. Schmid

A. Summary

The development of malignant lymphoma in myoepithelial sialadenitis with and without Sjögren's syndrome was investigated. At first, prelymphomatous proliferation areas showing a polytypic immunoglobulin (Ig) pattern were seen. These transformed into malignant lymphoma with a monotypic Ig pattern, at first in small, circumscribed proliferation areas ("early lymphoma") and later in large, confluent proliferation areas ("manifest lymphoma"). The lymphomas were classified as LP immunocytoma. In some cases they transformed into high-grade malignant lymphomas of the same category, namely, B-immunoblastic lymphoma. The same types of lymphoma have been found in NZB mice and chronic graft-versus-host reactions. "Primary" malignant lymphomas of salivary glands that did not show myoepithelial sialadenitis were also studied. These lymphomas were mostly germinal center cell tumors and probably developed primarily in lymph nodes within parotid glands in most, if not all, cases.

B. Introduction

In 1964, Talal and Bunim [8] recognized that there is a high frequency of malignant lymphoma among patients with Sjögren's syndrome. Later, Anderson and Talal [1] reported that the cells of the "histiocytic" lymphomas developing in Sjögren's syndrome showed a monoclonal immunoglobulin (Ig) pattern, usually IgM/ κ . Such lymphomas thus have to be interpreted

as B-immunoblastic lymphoma. In the same article, Anderson and Talal complained that their pathologist and some consultants were not able to diagnose a fair number of cases that showed monoclonal IgM/ κ , but did not exhibit an immunoblastic morphology. We speculate that those tumors were lymphoplasmacytic/lymphoplasmacytoid lymphomas (LP immunocytoma).

We also found it very difficult to interpret lymphoid infiltration of salivary glands. Thus new techniques have been applied to the cases in our collection. In particular, the immunoperoxidase method was used to demonstrate cytoplasmic Ig and lysozyme. Follow-up studies were also performed to learn more about the clinical picture and outcome. The latter investigations were initially done with the assistance of Drs. M. Burkert (Kiel), Renate Reif (Zrifin, Israel), and Dagmar Helbron (Kiel). Recently, we examined the material collected at the Lymph Node Registry in Kiel with regard to the following lesions:

1. Myoepithelial sialadenitis (MESA) with and without Sjögren's syndrome
2. So-called primary malignant lymphoma of salivary glands
3. Unclear lymphoid lesions of salivary glands.

C. Material and Methods

Paraffin sections from a total of 72 cases were stained with Giemsa, silver impregnation (Gomori), periodic acid Schiff (PAS), and hematoxylin and eosin (H & E).

	With MESA	Without MESA
ML lymphoplasmacytic/-cytoid (LP immunocytoma)	23 (3 ^a)	2
ML immunoblastic (B)	3 (3 ^a)	2
ML centroblastic-centrocytic	—	15
ML centroblastic	—	2
Hodgkin's disease	—	4
Total	26 (+6 ^a)	25

^a Cases showing only extrasalivary ML

A modification [3] of the immunoperoxidase method of Sternberger et al. [6] was used to demonstrate α , γ , μ , J, κ , and λ chains and lysozyme as described in detail elsewhere [4].

D. Results and Discussion

Myoepithelial islands are the essential feature of the sialadenitis seen in Sjögren's syndrome. There are isomorphic cases of sialadenitis, however, without the clinical features of Sjögren's syndrome. Thus we use the term "myoepithelial sialadenitis" (MESA) to designate all cases showing myoepithelial proliferation and lymphoid

infiltration of salivary glands. MESA was chosen as a distinguishing criterion for the present study. We simply separated lymphoid proliferation or malignant lymphomas with MESA and those without MESA.

The types of malignant lymphoma diagnosed on salivary gland biopsies are shown in Table 1. There was a significant difference in the occurrence of the various types of malignant lymphoma between the groups with and without MESA. Patients with MESA showed only LP immunocytoma or its high-grade malignant variant, B-immunoblastic lymphoma. In contrast, only a few of the patients without MESA had these types of lymphoma, while a majority showed germinal center cell tumors.

Table 2. Results of immunoperoxidase (PAP) staining and occurrence of extrasalivary lymphoma in 45 patients with myoepithelial sialadenitis (MESA)

	n	PAP	Extrasalivary lymphoma	
			with MESA	later (10 – 66 months)
MESA without proliferation areas	3			
Polytypic		3	—	—
MESA with small, circumscribed proliferation areas	16			
Polytypic		4	—	—
Monotypic		9	—	3
Not studied		3	—	1
MESA with extensive, confluent proliferation areas	26			
Polytypic		—	—	—
Monotypic		18	6	2
Not studied		8	2	4

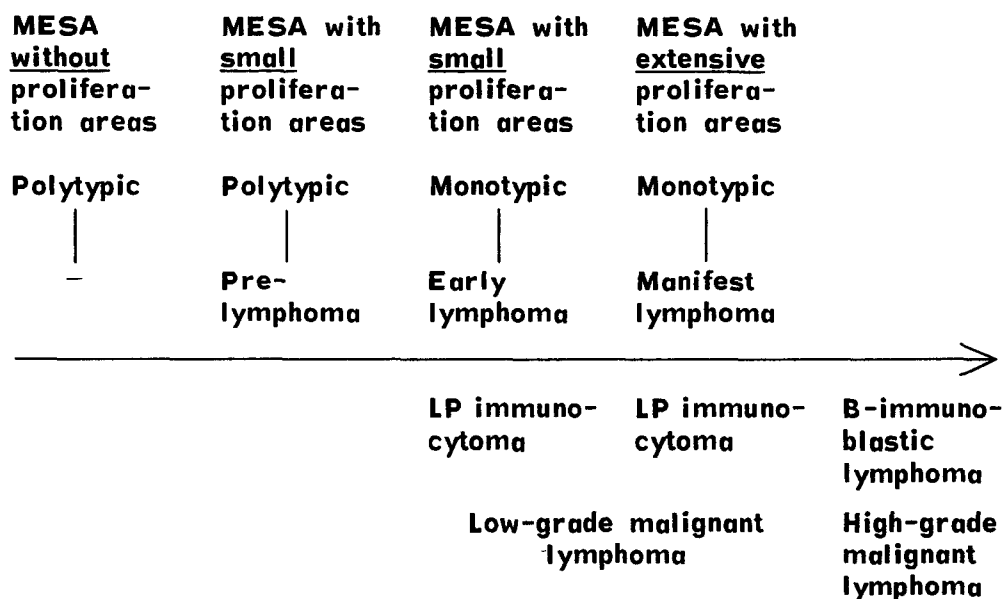


Fig. 1. Schematic diagram of development of malignant lymphoma in myoepithelial sialadenitis (MESA)

There were also four cases of Hodgkin's disease in the group without MESA and none in the group with MESA.

A remarkable finding in the cases without MESA was the very frequent presence of residual lymph node tissue. This indicates that most, if not all, of the malignant lymphomas developed in lymph nodes within salivary glands (specifically, parotid glands) and not in the salivary glands themselves. In contrast, we did not find residual lymph node tissue in any of the cases with MESA and thus assume that the lymphomas truly developed primarily in salivary glands.

An analysis of all our cases histologically characterized by MESA (see Table 2) revealed that the myoepithelial complexes were sometimes surrounded by uniformly dense infiltrates of lymphocytes with a few plasma cells; this pattern was found in three cases. A larger number of cases (16), however, showed small, circumscribed proliferation areas, while a majority (26) of the cases showed large, confluent proliferation areas. The proliferation areas contained large immunoblasts, a few medium-sized lymphoid cells, and plasmacytoid cells, and they often exhibited mitotic activity.

With immunoperoxidase staining, the plasmacytoid cells of MESA without proliferation areas showed a polytypic Ig pattern. The MESA group with small proliferation areas contained both polytypic and

monotypic cases. In the cases of MESA with large proliferation areas, the Ig pattern of the lymphoplasmacytoid proliferation areas was exclusively monotypic.

A malignant lymphoma of the same type as the salivary gland lymphoma sometimes developed in extrasalivary tissue. This occurred at the same time as MESA only in the cases with large proliferation areas, whereas later development of extrasalivary lymphoma was also seen in cases with small proliferation areas (see Table 2).

Assuming that a monotypic Ig pattern is solid evidence of malignant proliferation, it is possible to sketch the development of malignant lymphoma in MESA (Fig. 1). At first, MESA does not show proliferation areas and contains only plasma cells with a polytypic Ig pattern. Later, small proliferation areas showing a polytypic Ig pattern appear in the diffuse lymphoid infiltrates; we interpret this lesion as a prelymphoma. Finally, the Ig pattern becomes monotypic, and the small proliferation areas probably represent an early lymphoma. Such cases do not show any extrasalivary manifestation. After a latency period of 10–66 months, however, extrasalivary lymphoid proliferation is seen, and it shows the same morphology as the salivary gland, namely, that of LP immunocytoma.

MESA with extensive, confluent proliferation areas always has a monotypic Ig pattern and can probably be interpreted as

manifest malignant lymphoma (specifically, LP immunocytoma). This view is supported by the simultaneous presence of a malignant lymphoma with the same morphology (LP immunocytoma) outside the salivary gland in some cases.

In a few cases, the LP immunocytoma, especially if it was extrasalivary, was observed to transform into B-immunoblastic lymphoma. Since this lymphoma type is the high-grade malignant variant of LP immunocytoma, the final stage of development has been reached. As outlined in Fig. 1, an initially benign proliferation ("prelymphoma"; small proliferation areas, polytypic Ig pattern) leads to an early lymphoma (small proliferation areas, monotypic Ig pattern), which develops into a manifest lymphoma (large proliferation areas, monotypic Ig pattern). The lymphoma is always LP immunocytoma, which is a low-grade malignant lymphoma according to our classification. This low-grade malignant lymphoma may transform into a high-grade malignant lymphoma of the same cell series, namely, B-immunoblastic lymphoma.

It is not possible to determine the incidence of such lymphoma development, because the material collected at the Lymph Node Registry is highly selected.

Analysis of the Ig classes in the immunoblasts and plasmacytoid cells of the monotypic cases revealed a marked predominance of IgM/ κ . There were also a few cases with IgM/ λ , IgG/ κ , or IgA/ λ .

It is not always possible to determine from the morphology alone whether a proliferation has a monotypic or polytypic Ig pattern. Nevertheless, the following criteria were found to be of some help: epithelioid cells and intranuclear PAS-positive inclusions occurred only in proliferation areas with a monotypic Ig pattern, and giant cells of Sternberg-Reed type were seen almost only in such areas.

In order to interpret our findings, it may be helpful to compare them with reports on similar lesions in animals. MESA is now considered to be an immunosialadenitis and is placed in the group of autoimmune disorders. A similar type of sialadenitis has been seen in NZB mice [7, 9] that spontaneously developed an autoimmune disease comparable to Sjögren's syndrome.

Similar lesions have also been found by Gleichmann et al. [2] in salivary glands of mice with chronic graft-versus-host reactions and by Shulman et al. [5] in chronic graft-versus-host syndrome in man. Moreover, in NZB mice and mice with chronic graft-versus-host reactions, the same types of malignant lymphoma develop as in MESA, namely, LP immunocytoma with macroglobulinemia and B-immunoblastic lymphoma.

Because of the types of malignant lymphoma found in chronic graft-versus-host reactions and the similarity in pathogenesis between autoimmune disorders and chronic graft-versus-host syndrome, we may speculate that the basic mechanisms behind the development of malignant lymphoma in both diseases are the same. According to Gleichmann et al. [2], this mechanism is produced by histoincompatibility between B cells, which might be virus infected, and the controlling T cells, which stimulate the "not self"-looking B cells to proliferate. It has not yet been determined whether this T-cell stimulation is enough for the final development of a malignant B-cell proliferation, or whether a second factor is necessary.

The development of LP immunocytoma and B-immunoblastic lymphoma in a defined experimental and immunologic situation not only provides indications regarding their developmental mechanism; it also shows that LP immunocytoma and B-immunoblastic lymphoma are clearly identifiable entities. Indeed, we must differentiate them in order to gain insight into the genesis of malignant lymphomas. Placing these entities in the same categories with other lymphoma types [as in the Working Formulation (10)] would obscure pathogenetic relationships.

References¹

1. Anderson LG, Talal N (1971) The spectrum of benign to malignant lymphoproliferation in Sjögren's syndrome. *Clin Exp Immunol* 9:199-221

¹ See Schmid et al. (1982) for a complete list of references

2. Gleichmann E, Melief CIM, Gleichmann H (1978) Lymphomagenesis and autoimmunization caused by reactions of T-lymphocytes to incompatible structures of the major histocompatibility complex: A concept of pathogenesis. *Cancer Res* 64:292-315
3. Mepham BL, Frater W, Mitchell BS (1979) The use of proteolytic enzymes to improve immunoglobulin staining by the PAP technique. *Histochem J* 11:345-357
4. Schmid U, Helbron D, Lennert K (1982) Development of malignant lymphoma in myoepithelial sialadenitis (Sjögren's syndrome). *Virchows Arch (Pathol Anat)* 395:11-43
5. Shulman HM, Sullivan KM, Weiden PL, McDonald GB, Striker GE, Sale GE, Hackman R, Tsoi M-S, Storb R, Thomas ED (1980) Chronic graft-versus-host syndrome in man. A long-term clinicopathologic study of 20 Seattle patients. *Am J Med* 69:204-217
6. Sternberger LA, Hardy PH Jr, Cuculis JJ, Meyer HG (1970) The unlabeled antibody enzyme method of immunohistochemistry. *J Histochem Cytochem* 18:315-333
7. Talal N (1974) Autoimmunity and lymphoid malignancy in New Zealand black mice. *Prog Clin Immunol* 2:101-120
8. Talal N, Bunim II (1964) The development of malignant lymphoma in the course of Sjögren's syndrome. *Am J Med* 36:529-540
9. Taylor CR (1976) Immunohistological observations upon the development of reticulum cell sarcoma in the mouse. *J Pathol* 118:201-219
10. The Non-Hodgkin's Lymphoma Pathologic Classification Project (1982) National Cancer Institute Sponsored Study of Classifications of Non-Hodgkin's Lymphomas. Summary and description of a working formulation for clinical usage. *Cancer* 49:2112-2135