

Dyserythropoiesis in Acute Lymphoblastic Leukemia of Childhood*

O. Hrodek, I. Stará, and J. Šrajcr

A. Introduction

The purpose of this study was to review bone marrow appearances of erythroid cells in children with acute lymphoblastic leukemia (ALL) in order to assess the extent of dyserythropoiesis at two phases of disease: at diagnosis and after multidrug induction treatment at the beginning of complete remission.

B. Materials and Methods

A total of 15 morphological abnormalities characteristic of dyserythropoiesis were evaluated in bone marrow smears stained with May-Grünwald-Giemsa stain. Abnormalities were classified as: (a) anomalies of the nucleus (binuclearity, multinuclearity, nuclear lobulation, budding, fragmentation, chromatin lumping and pyknosis, intranuclear bridging, extrusion of the nucleus); and (b) anomalies of the cytoplasm (cytoplasmic connections, basophilic stippling, Howell-Jolly bodies, atypical mitotic figures, asynchrony of nuclear cytoplasmic maturation, megaloblastic changes).

A group of 23 children with ALL of different immunologic subtypes were investigated at diagnosis and after successful induction of first complete remission. According to multidrug induction regimen

two groups of patients were compared: 8 patients with a two- or three-drug regimen (2 children with prednisone and vincristine, 6 children with prednisone, vincristine, and rubidomycin), and 15 patients with a four- or five-drug regimen (prednisone, vincristine, rubidomycin or adriamycin, plus cytosine arabinoside, L-asparaginase, or cyclophosphamide). The mean frequency of all anomalies per 100 erythroid cells and the absolute frequency of the individual anomalies (number of signs observed in all cases) were statistically tested. A logarithmic normal distribution of data was found and, therefore, a logarithmic transformation was used in comparison of means.

C. Results

The percentage of erythroblasts in the bone marrow at diagnosis was greatly reduced (Fig. 1). The mean of all cases investigated was 3.1% and reflected a quantitative decrease of erythropoiesis. After complete remission, it was significantly increased to 26% ($P < 0.01$). The mean frequency of dyserythropoietic signs per 100 erythroblasts was 12.5 at diagnosis and 60.9 at the beginning of complete remission ($P < 0.01$).

The most significant increase ($P < 0.001$) was found in megaloblastosis (from 89 to 524), then in cytoplasmic connections (from 15 to 144) and in basophilic stippling (from 39 to 195). Other significant increases ($P < 0.01$) occurred in Howell-Jolly bodies, asynchrony of nuclear cytoplasmic maturation, blurred structures of nucleus,

* 2nd Dept. of Paediatrics, Charles University, Prague, Czechoslovakia

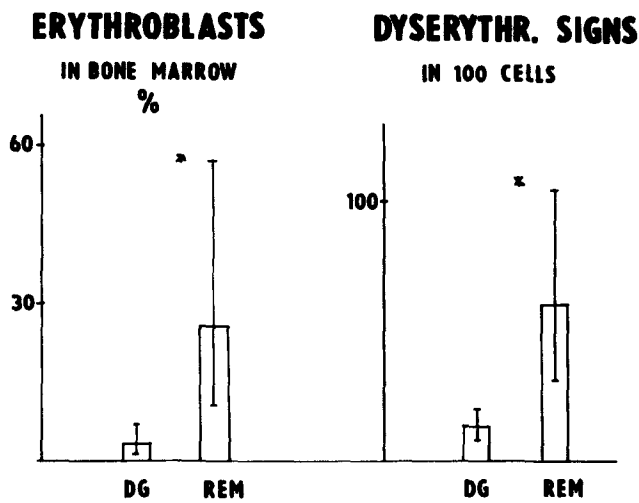


Fig. 1. Proportion of erythroblasts and frequency of dyserythropoietic signs in the bone marrow at diagnosis (DG) and after achieving complete remission (REM)

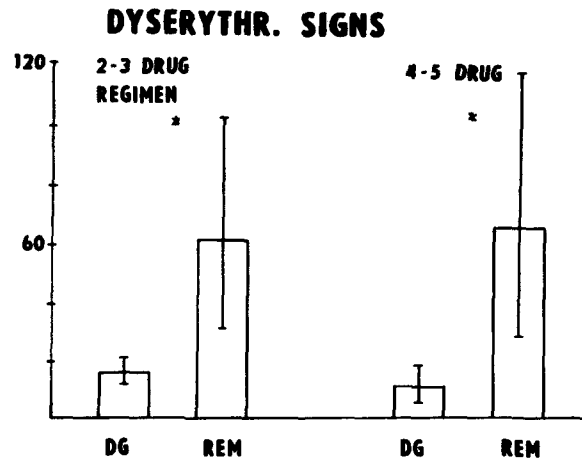


Fig. 2. Frequency of dyserythropoietic signs in the bone marrow at diagnosis (DG) and after achieving complete remission (REM) with less intensive and more intensive induction therapy

binuclearity, nuclear lobulation, budding, fragmentation, and chromatin lumping or pyknosis. The increase of all remaining abnormalities, such as multinuclearity, nuclear bridges, premature extrusion of nucleus, and atypical mitotic figures, was less significant ($P < 0.05$).

Dyserythropoietic changes in 8 children with less intensive induction therapy (two- or three-drug regimen) were compared with 15 children with more intensive regimens (four- or five-drug regimen). The mean frequency of abnormalities at diagnosis and the increase at the beginning of complete remission were the same (Fig. 2). There was no significant difference between the two groups investigated.

D. Discussion and Conclusions

The present study has shown the extent to which morphological abnormalities in

erythroid cells occur as part of hematologic pattern in ALL and as a consequence of multidrug induction chemotherapy. Many of the morphological manifestations occur as a result of disturbances of mechanisms which regulate the cell cycle and normal mitosis, normal hemoglobin synthesis, and other protein synthesis. Other manifestations are probably degenerative or due to increased cell fragility. From the static pictures of cells as seen in marrow aspirates, however, it is difficult to deduce dynamic processes involved in the abnormal, functionally inefficient erythropoiesis. More complex studies are necessary to elucidate the connections between morphological and functional defects of erythroid marrow cells and their clinical significance in children with ALL. The effect of more or less aggressive drug regimens can be established after collecting data from larger series of patients treated with the same protocol.